



A.D. MDLXII

**UNIVERSITA' DEGLI STUDI DI SASSARI**  
SCUOLA DI DOTTORATO DI RICERCA IN SCIENZE BIOMEDICHE  
Direttore: Prof. E.Tolu

---

**Indirizzo: Fisiologia, Farmacologia, Morfologia  
e Fisiopatologia del Sistema Nervoso**

XXIII CICLO

Vertebral augmentation with nitinol endoprosthesis:  
clinical experience with one year follow up in 40 patients

Coordinatore: Chiar.mo Prof. Eusebio Tolu

Tutor: Chiar.mo Prof. Andrea Montella

Dottorando: Dott. Antonio Manca

Anno Accademico 2009-2010

## **Acknowledgements -Ringraziamenti**

*Al Dott. Giovanni Carlo Anselmetti,  
per avermi insegnato una professione*

*Ai miei genitori, per avermi insegnato tutto il resto*

*Al Prof. Andrea Montella ed al Dott. Andrea Carai  
per l'incoraggiamento ed il supporto*

*A Silvia, per la pazienza e la dedizione*

*To Dr. Giovanni Carlo Anselmetti,  
for teaching me a profession*

*To my parents, for teaching me all the rest*

*To Prof. Andrea Montella and Dr. Andrea Carai,  
for the encouragement and support*

*To Silvia, for the patience and dedication*

## **Disclosures**

The author has currently no commercial interest to disclose.

“VerteLift™ implant and VerteLift delivery devices were provided to the Institution at no-charge by SpineAlign Medical, Inc.

Thanks to J. Chris McAuliffe (Chief Operating Officer), Amy Forro (Director of Clinical Affairs) and Aaron La Casse (Product Manager and Clinical Specialist) of SpineAlign Medical, Inc. for the support.

## Chapter One

### INTRODUCTIVE PART

#### Vertebral Augmentation: Literature review

<b>Introduction</b>	page 5
- Indications and Contraindications	page 6
- Clinical Examination	page 9
- Imaging	page 11
- Fracture Age	page 13
- Vertebroplasty and Kyphoplasty	page 14
- Mechanisms of pain relief	page 14
-	
<b>Technique</b>	page 20
<b>Results</b>	<b>page 21</b>
- Pain relief and quality of life improvement	page 21
- Immediate and short-term results	page 21
- Long term results	page 22
- New fractures	page 24
- Complications	page 26
- Vertebroplasty vs placebo	page 27
- Vertebral height increase	page 31
- Vertebroplasty and Kyphoplasty vs conservative treatment	page 32

## Chapter Two

### EXPERIMENTAL PART

#### Vertebral augmentation with nitinol endoprosthesis: clinical experience with one year follow up in 40 patients

<b>Aim</b>	<b>page 37</b>
<b>Materials and Methods</b>	<b>page 37</b>
- Patient selection	page 37
- Technique	page 39
- Device	page 41
- Radiological assessment and - vertebral height measurements	page 43
- Pain and Quality of life assessment	page 44
- Statistic analysis	page 44
<b>Results</b>	<b>page 45</b>
<b>Discussion</b>	<b>page 51</b>
<b>Conclusion</b>	<b>page 54</b>
<b>Tables and Images</b>	<b>page 37</b>
<b>References</b>	<b>page 64</b>

## Introduction

Percutaneous vertebral augmentation are all minimally invasive procedures aimed to obtain pain relief, vertebral consolidation and height restoration in symptomatic vertebral fractures and lesions. All of these procedures are performed under radiologic guidance (usually fluoroscopy and Computed Tomography) gaining percutaneous access to vertebral bodies through needles and cannulas. The meaning of vertebral augmentation should imply the aim of increasing vertebral height, therefore is commonly intended for procedures specifically designed for that purpose such as kyphoplasty and vertebral endoprosthesis placement. Nevertheless vertebroplasty is also able to provide vertebral height restoration in unstable fractures and Kummel's disease or when performed with thicker cements.

Vertebroplasty is furthermore included in a consensus statement on percutaneous vertebral augmentation recently developed by the American Society of Interventional and Therapeutic Neuroradiology, Society of Interventional Radiology, American Association of Neurological Surgeons/Congress of Neurological Surgeons, and American Society of Spine Radiology<sup>1</sup>.

The first vertebral augmentation procedure can thus be considered the vertebroplasty performed in 1984 by Hervè Deramond, a French interventional radiologist, treating an aggressive angioma of the second cervical vertebra<sup>2</sup>. In 1991 vertebroplasty was then performed to treat osteoporotic fractures<sup>3</sup> and later on for the symptomatic treatment of spinal metastases and vertebral

fractures due to multiple myeloma<sup>4-6</sup>; vertebroplasty found further applications for rarer painful vertebral lesions such as the ones related to Langherans disease<sup>7</sup> and osteogenesis imperfecta<sup>8</sup>.

In 1998 Mark Reiley, an American orthopedic surgeon, conceived and patented a bone tamp designed to be inflated inside the collapsed vertebra in order to lift the endplates before cement injection aiming to achieve height restoration and kyphosis reduction in addition to pain relief<sup>9,10</sup>

More recently some permanent endoprostheses have been designed to be percutaneously introduced inside collapsed vertebral bodies and then encased in bone cement. “Prosthesis –assisted” kyphoplasty should avoid vertebral elastic recoil following balloon/device deflation and withdrawal because expanded permanent prostheses are able to maintain the gained vertebral height during bone cement injection.

### ***- Indications and contraindications***

Vertebral augmentation can be considered as part of pain management and thus the common indication of the different percutaneous spine interventions should be “back pain” clinically amenable to a pathologic vertebral condition (fracture or lesion) found with radiological imaging. All vertebral augmentation procedures can provide pain relief but any of them have different features and should be tailored to each case.

As vertebroplasty is the oldest among vertebral augmentation procedures is also the one that gained the widest consensus on its application.

In 2009 an official practice guideline on vertebroplasty was created collaboratively by the American College of Radiology (ACR), the American Society of Neuroradiology (ASNR), the Society of Neurointerventional Surgery (SNIS), the American Society of Spine Radiology (ASSR), and the Society of Interventional Radiology (SIR)<sup>11</sup>. Indications and contraindications of percutaneous vertebroplasty were stated as follows:

***Indications:***

1. Painful osteoporotic or neoplastic vertebral compression fracture(s) refractory to medical therapy.
2. Symptomatic vertebral body microfracture (as documented by magnetic resonance imaging [MRI] or nuclear imaging, and/or lytic lesion seen on CT) without obvious loss of vertebral body height.

Guidelines published by Society of Interventional Radiology (SIR) in 2003<sup>12</sup> were more specific about the kind of fracture to be treated with vertebroplasty.

1. Painful primary and secondary osteoporotic vertebral compression fracture(s) refractory to medical therapy.
2. Painful vertebrae with extensive osteolysis or invasion secondary to benign or malignant tumor (ie, hemangioma, multiple myeloma, or metastatic disease).
3. Painful vertebral fracture associated with osteonecrosis (Kummell Disease).

SIR guidelines stress the precise indication of vertebroplasty in vertebral osteonecrosis, also called Kummell's disease, that is an unhealed and mobile chronic fracture with gas and/or fluid collections within vertebral body. This painful pathologic condition, often misdiagnosed, is maybe the one that benefit most from vertebroplasty (as bone cement stops vertebral fracture motion) and less from conservative treatment (as osteonecrotic bone has a slow and difficult healing).

With the Consensus Statement on vertebral augmentation developed in 2007<sup>1</sup>, on the basis of available literature review, was determined that the clinical outcome in patients treated with kyphoplasty is comparable to that seen in patients treated with vertebroplasty. In the absence of a proven advantage of one procedure over the other regarding pain relief, vertebral height restoration, or complication rate both vertebral augmentation procedures are considered established, safe and effective treatment for painful compression fractures.

No official guidelines have currently defined different indications and contraindications for vertebroplasty and kyphoplasty.

The previously cited guidelines from ACR<sup>11</sup> stated what follows regarding contraindications on vertebroplasty:

#### ***Absolute Contraindications***

1. Asymptomatic vertebral body compression fractures.
2. Active osteomyelitis of the target vertebra.
3. Uncorrectable coagulopathy.
4. Allergy to bone cement or opacification agent.
5. Patient improving on medical therapy.
6. Prophylaxis in osteoporotic patients (unless being performed as part of a research protocol).
7. Myelopathy originating at the fracture level.

#### ***Relative Contraindications***

1. Radiculopathy in excess of local vertebral pain, caused by a compressive syndrome unrelated to vertebral collapse. Occasionally preoperative vertebroplasty can be performed before a spinal decompressive procedure.
2. Retropulsion of a fracture fragment causing severe spinal canal compromise.
3. Epidural tumor extension with significant encroachment on the spinal canal.
4. Ongoing systemic infection.



Severe vertebral collapses, also called “vertebra plana”, were considered in the past as a relative contraindication for vertebroplasty<sup>13</sup>. The treatment of such fractures has already been reported in the past<sup>14,15</sup> with good outcomes and are no longer an issue for skilled physicians with adequate angiographic equipment and are not listed among contraindications in official guidelines anymore.

Relative contraindications of vertebral augmentation other than those cited in official guidelines depend upon operator’s skills and the ability of the patient to lie in the prone position long enough during intervention<sup>16</sup>.

#### ***- Clinical examination***

Clinical examination and interview with the patient undergoing vertebral augmentation are fundamental in the pre-procedural assessment.

Vertebral augmentation procedures are intended for pain management and thus imaging findings must match with clinical symptoms. Back pain is a common symptom as much as vertebral deformities are frequent radiological findings thus we must exclude different painful causes to avoid “image treatment” instead of pain treatment.

Pain at palpation over spinous processes corresponding to the fractured level represents an important clinical feature in order to match image and symptoms especially in patients with multiple fractures with different “ages” or with multiple metastases. The presence or absence of the so called “*tenderness point*” shouldn’t be a mandatory feature: a paper by Gaughen et al. showed that the lack of this sign didn’t affect clinical outcome<sup>17</sup>.

Additional information regarding pain features can be obtained by clinical interview as each fracture or lesion has different pain onset depending on the anatomic site. Usually when the mid-thoracic spine is involved the patient perceives pain between the scapulas during coughing, breathing, sneezing or during trunk torsion. When the thoraco-lumbar region is affected the patient feels pain during trunk flexions or while getting up from the bed (typically patients can't raise themselves into a sitting position). When the lumbar region is affected pain is exacerbated from a prolonged sitting or standing position depending if the mid-lumbar or lumbo-sacral vertebrae are involved. As for any pain procedure, perceived pain, quality of life and pain medication must be quantified at baseline in order to assess the clinical outcome of the procedures.

There are plenty of questionnaires, indexes and scores available that can be used to evaluate pain, mobility and quality of life before treatment and during follow up. In a review from Davidson et al.<sup>18</sup> 24 different questionnaires on quality of life and "back pain" assessments were found on Medline; among these only five met authors' criteria in terms of clinical relevance, reliability and simplicity (considering the old mean age of the treated population): modified Oswestry Disability Questionnaire, Quebec Back Pain Disability Scale, Roland-Morris Disability Questionnaire, Waddell Disability Index, and 36-Item Short-Form Health Survey (SF-36). Most of these questionnaires are very complete because they assess global quality of life including pain, mobility, physical and psychic wellness but, on the other hand, their length and

complexity represent a limitation considering the older age of the target population. *Visual Analogue Scale (VAS score)* first introduced from Huskisson in 1979<sup>19</sup>, is a basic and intuitive method where the patient is asked to indicate his pain on a given number on a 10 cm ruler (considering 0 as no pain at all and 10 as the worst pain ever felt in life). More often it is simply used to ask the patients to rate their perceived pain “from 0 to 10” and it can easily be asked in phone interviews during follow up. Ease of use of the VAS make this assessment applicable to patients of any age, mental status and culture; even if it is less complete of other questionnaires a VAS drop in score leads to a quality of life improvement.

### ***- Imaging***

Diagnostic imaging has a key role in patient’s selection together with clinical evaluation. Often patients with back pain come to observation with plain radiographs showing a wedge fracture. These patients have to be further investigated with magnetic resonance imaging (MRI) as it’s the only imaging technique able to evaluate musculoskeletal and neurological structures with the highest contrast resolution on bone, cord, nerves and disks.

Many authors demand MRI as pre-operative evaluation<sup>20</sup> because is able to identify benign and malignant lesions before these are visible on CT and, with fat-suppressed sequences, are able to evaluate “age” and “healing” of a fracture.

Mathis et al. in a review of 2001<sup>20</sup> found that hyperintensity in fat suppressed sequences Short Tau Inversion Recovery (STIR), as sign of bone marrow edema and therefore of recent fracture, was a useful tool for the selection of vertebral levels to be treated. More recently Tanigawa et al. prospectively treated 80 osteoporotic patients presenting with high, mild or absent hyperintensity on fractured vertebrae with percutaneous vertebroplasty and found that the presence of bone marrow edema is significantly predictive of a good clinical outcome of the procedure<sup>21</sup>.

Bone scintigraphy should not be considered as a pre-procedural routine imaging due to its lack of anatomical information but can be useful in cases of multiple fractures where increased drug uptake can highlight higher metabolism therefore finding the source of pain<sup>22</sup>. Kallmes et al.<sup>23</sup> described a case with many collapsed vertebrae and no hyperintensity on fat-suppressed MRI sequences where the single level showing uptake was treated with vertebroplasty obtaining pain relief.

Computer tomography (CT) can take place of MRI when the latter is contraindicated (claustrophobia, presence of pace-makers or prostheses) or can be integrated with other imaging modalities taking advantage of its higher spacial resolution on bone matrix and cortex. CT scan, readily available and commonly performed in oncologic patients during follow up, can be acquired with a thin slice protocol and post-processed with multiplanar reconstructions obtaining a precise depiction of fractures and clefts in the bone. Furthermore CT scan can clearly determine whether a metastatic lesion is osteolytic,

depicting gaps of cortical bone where bone cement can leak, or osteoblastic where vertebral augmentation is usually contraindicated.

If we need to find an “ideal” second level pre-procedural imaging modality for vertebral augmentation we should finally choose MRI because it’s the one that merges the higher anatomical information on a wider spectrum of spinal structures with a good functional information provided by signal features in basal sequences (calcium, blood, air, water, edema), spectroscopy (metabolites) and contrast administration (vascularization).

### ***- Fracture Age***

In osteoporotic patients vertebroplasty is usually performed after 4-6 weeks of conservative treatment without evidence of clinical benefit<sup>24-28</sup>. This is justifiable because more than 50% of patients eligible for vertebroplasty can have fracture healing and pain relief just with brace support, bed rest and pain medication alone<sup>29</sup>. Fracture age shouldn’t affect vertebroplasty outcome as found by Kauffman et al<sup>30</sup> with the exception of older patients with chronic usage of analgesics possibly due to the dependency. Brown et al. found in a retrospective study no statistically significant difference in pain relief obtained after vertebroplasty in patients treated for sub-acute fractures or chronic fractures less than 12 months while clinical outcome in terms of pain relief was worse for patients with vertebral fractures older than 24 months<sup>31</sup>.

### ***- Vertebroplasty and Kyphoplasty***

Based on vertebroplasty experience kyphoplasty was introduced in the late nineties<sup>9,32</sup>. Kyphoplasty is performed with the intent of restoring vertebral height and correct kyphosis in traumatic or osteoporotic fractures less than 3 month old but it adds higher costs and risks to vertebroplasty without evidence of a better outcome<sup>33</sup>. Indications, contraindications and effectiveness of the procedure have been debated for a long time and a recent literature meta-analysis concluded that both vertebral augmentation procedures are comparable in terms of clinical outcome and new vertebral fracture rate<sup>34</sup>. Nevertheless meta-analyses are affected by intrinsic limits with these kinds of studies and further investigations like large randomized controlled trials on vertebroplasty versus other vertebral augmentation procedures are warranted.

### ***- Mechanisms of pain relief***

The underlying mechanisms postulated for pain relief provided by bone cement injected during spine interventions are mainly three: chemotoxicity of methyl methacrylate, thermal necrosis during polymerization exothermy and stabilizing effect provided by cured cement<sup>35</sup>.

A “chemical effect” was postulated for pain relief as the most used bone cement for spine interventions is polymethylmetacrylate (PMMA) that contains a monomer component known to have toxic effects on cells<sup>36</sup> and potential neurotoxicity<sup>37</sup>. Nevertheless this hypothesis is invalidated by the good clinical outcome recently demonstrated in a matched case-controlled study of

vertebroplasty with calcium phosphate cement (not containing any toxic monomer) compared with conservative treatment <sup>38</sup>.

Thermal necrosis of vertebral nerve endings due to PMMA polymerization exothermy has been also advocated in the past<sup>39</sup> as a cause of pain relief on the basis of old papers, mainly aimed to investigate effects of large amounts of PMMA used to cement total hip prostheses, finding that cylinders with diameters from 5 mm to 30 cm can reach peak temperatures from 41° to 122°C during polymerization<sup>40</sup>. As previously reported in animal studies and often cited in papers about bone intervention, thermal necrosis in bone tissues occurs if temperatures >50°C are maintained for more than 1 minute <sup>41</sup> while injury to sensory nerves occurs at 45° C for more than 30 minutes <sup>42</sup>. Some *ex vivo* studies have been done monitoring the temperature of PMMA and surrounding tissue during cement polymerization but these were performed on cadaveric specimens placed in saline bath heated at 37 °C that can just partially simulate the *in vivo* condition because don't take into account the lowering of temperature caused by the convective effect of flowing blood and cerebrospinal fluid <sup>39,43</sup>. Furthermore the simulated vertebroplasties were performed with bipedicular or bilateral (in the study from Belkoff et al. <sup>43</sup> pedicles were removed) injection of large amounts of PMMA that is quite far from current clinical practice: 10 ml were injected in the study performed by Deramond et al. <sup>39</sup> and from 6 mL to 10 mL in the study from Belkoff et al. <sup>43</sup>

Additionally in an *in vivo* animal study <sup>44</sup> it was physiologically demonstrated that the local temperature did not reach values that are known to cause tissue necrosis but the average amount of PMMA injected (0.8 ml) was significantly

lower than commonly used in vertebroplasty. In this study PMMA contained only 13% barium sulfate as opacifier (25%–35% BA is the norm), the procedure was not performed percutaneously and the probes were placed only in the bone-cement interface.

To date the only human *in vivo* measurement of polymerization temperature of several different bone cements was the one performed during the current PhD course and recently published by Anselmetti et al<sup>45</sup>. Eleven different bone cements were injected in 22 patients to treat 22 osteoporotic fractures with a monolateral approach. A radiofrequency thermal ablation (RFA) needle carrying five thermocouples, was than coaxially inserted through a vertebroplasty needle placed contralaterally. The hooks of the RFA needle were opened in order to deploy each thermocouple in a reproducible position as follows: within the anterior third (T5), and in the mid part of the vertebral body (T2), close to the superior (T1) and inferior (T3) endplates, and near the lateral left wall (T4). Consequently, thermocouples T2 and T5 were embedded in the cement, while T1, T3, and T4 were in the bone-cement interface. The amount of PMMA injected was 3 mL per vertebra while when using Cortoss (bis GMA) 2mL per vertebra were injected as this bone cement is reported to have higher cancellous bone perfusion rates compared to PMMA<sup>46</sup>.

Using the average peak temperature values recorded during the study, the bone cements were categorized into three groups: Group A (Confidence and Mendec Spine), where the mean peak temperature value measured >60 °C; Group B (Osteopal V, Spinefix, Parallax, CementoFixx, Vertebroplastic, KyphX HV-R,



Osteofirm) with a mean peak temperature between 50 °C and 60 °C; and Group C (Ava-tex and Cortoss) with a recorded mean peak temperature <50 °C.

Peak temperature values (always measured on thermocouple T2) for vertebrae injected with Confidence and Mendec Spine (Group A,  $86.7 \pm 10.7$  °C) were significantly higher ( $p = 0.0172$ ; 95% CI, -43.523 to -8.834) than those injected with the PMMA bone cements categorized in Group B ( $60.5 \pm 3.7$  °C) and those belonging to Group C (mean,  $44.8 \pm 2.6$  °C;  $p = 0.0047$ ; 95% CI, -59.411 to -24.339). A higher peak temperature was always measured on the thermocouples (T2 and T5) placed in the medial and anterior part of the vertebral body, where a higher concentration of bone cement was always delivered.

Variation of median peak values among the bone cement groups was extremely significant ( $p = 0.0004$ , Kruskal–Wallis test). The average of all thermocouples showed an extremely significant temperature difference ( $p = 0.0002$ , Kruskal–Wallis test) among Group A (median, 69.05), Group B (median, 55.60), and Group C (median, 44.40).

While Cortoss and Ava-Tex (Group C) never reached 50 °C every PMMA in Groups A and B showed an average dwell time longer than 1 minute (average of all,  $2 \text{ min } 25 \text{ s} \pm 1 \text{ min } 17 \text{ s}$ ) potentially causing bone necrosis<sup>41</sup>, with the longer dwell time > 5 min recorded for Osteopal-V (average,  $5 \text{ min } 7 \text{ s} \pm 28 \text{ s}$ ). None of the tested bone cements maintained a temperature value of 45 °C for more than 30 minutes, which is necessary to achieve complete injury to the sensory nerves<sup>42</sup>

The results of this study suggest that thermal damage to intraosseous neural tissue and periosteal sensory nerves can be ruled out as the main mechanism in the clinical results of PV, such as pain relief. Furthermore the same clinical results are achieved using either relatively high-temperature PMMA (Groups A and B)<sup>34</sup> or low temperature cements (Group C) as Cortoss<sup>47,48</sup>.

There are few case reports of histologic findings in treated vertebrae documenting the necrotizing capabilities of PMMA: in one cadaveric specimen of a metastatic vertebra treated with vertebroplasty a necrotic rim up to 6 mm was found around PMMA<sup>49</sup> while, on the other hand in another cadaveric study performed on four vertebral specimens of two patients undergone both vertebroplasty (one vertebra) and kyphoplasty (three vertebrae) for osteoporosis the authors could identify only rare foci of necrosis in the harvested vertebral bodies, suggesting that if the feared thermal necrosis occurred during PMMA curing, most of the bone must have been remodeled by the time of specimen retrieval<sup>40</sup>. A recent animal *in vivo* study showed the possibility of bone necrosis and no neural tissue necrosis at histology<sup>50</sup>

Once “chemical effect” and “thermal effect” have been excluded or minimized as causes of denervation, the most probable mechanism of pain relief remains mechanical stabilization.

Inner innervation of the vertebral body is provided by the basivertebral nerve, entering with the homonymous vein through the foramen of the posterior vertebral wall, and its roots within the trabecular bone up to endplates<sup>51</sup>. These nerve fibers have been found to produce substance P, which is strictly involved

in nociception, thus providing strong evidence that the vertebral cancellous bone itself can also be a source of pain<sup>52</sup>.

Most of the pain due to a vertebral fracture should rely on the stimulation of vertebral nociceptors and substance P production. During fluoroscopic examination of a vertebral fracture is quite common to see endplate motion if a cleft due to osteonecrosis is present. Mc Kiernan et al. prospectively investigated 50 patients under fluoroscopy, before vertebroplasty, finding fracture mobility with presence of a cleft in 24 of them (48%)<sup>53</sup>. Typically patients with mobile fractures perceive pain during breathing, coughing or flexing the trunk depending on the fracture site. Pain should be mainly related to the motion of the endplates in Kummell's disease (also because these are often the only surviving parts of the necrotic vertebral body) and to micro-motion of trabecular fractures; both these conditions are common histologic findings in osteoporotic fractures<sup>54</sup>. This also explains the "miracle effect" of immediate pain relief after cement curing (also when low exothermy or anexohermic cement are used) that leads to stopping of the cleft motion after vertebroplasty or other vertebral augmentations.

The variable amount of PMMA (from 2 to 6 ml) needed to be injected in a fractured vertebral body to obtain restoration of original biomechanical properties and thus provide pain reduction suggests the importance of a good mechanical stabilization in clinical outcome<sup>55</sup>.

## Technique

Even if a consensus has been reached between different societies of surgeons and radiologists giving birth to official guidelines on indications and contraindications, there are still differences in some technical aspects of the procedure given by different learning curves, habits, skills or beliefs.

There is no evidence of the utility of pre-procedural antibiotics and there are no studies on a better prophylaxis for vertebral augmentation. Some authors administer antibiotics intravenously during the procedure (usually Cefazolin) to all patients undergoing spine percutaneous interventions while others do it only in immunocompromised patients<sup>23</sup>.

Vertebral augmentation can be painful especially during cement injection due to pressure increase inside the vertebral body. Procedures can be performed under local anesthesia (usually lidocaine or similar) administered subcutaneously and over periosteum, as it is well tolerated from most patients. Some authors perform spinal interventions during mild sedation and analgesia using fentanyl and midazolam<sup>56</sup> while others, especially among surgeons, prefer endotracheal intubation and general anesthesia.

Vertebral augmentation was initially performed with combined CT and fluoroscopic guidance<sup>57</sup> (placing the portable C-arm in front on CT gantry) in order to precisely insert the needles taking advantage of CT and monitoring cement injection under fluoroscopy. With current technical skills acquired it is now possible to perform most of thoraco-lumbar vertebrae under fluoroscopic

guidance using CT guidance only for cervical levels, higher thoracic vertebrae and sacrum. Nowadays angiographic suites can acquire CT-like scans thus providing a better fluoroscopic guidance and CT advantages in a “all-in-one” machine<sup>58</sup>.

To gain access to vertebral bodies to be treated, needles are usually introduced with transpeduncular approach for lumbar levels and through costo-transversary joints in thoracic levels. If the needle tip crosses the midline, unipedicular approach is usually enough for vertebroplasty<sup>59</sup> while for kyphoplasty a bilateral approach is required. For vertebral prostheses the approach can be unilateral or bilateral depending on the number of devices required per level. A biomechanic study by Tohmeh et al. showed no significant difference between unilateral and bilateral cement distribution in vertebroplasty<sup>60</sup>.

After the needle has been correctly positioned vertebral consolidation is performed by injecting bone cement, usually polymethylmetacrylate (PMMA), inside vertebral body. PMMA can interdigitate with trabeculae (vertebroplasty), can fill up a cavity formed after balloon inflation (kyphoplasty) or can surround vertebral endoprostheses.

Biomechanical studies showed that an amount of PMMA equal to 2 ml per level is enough to restore strength and stiffness of the collapsed vertebra<sup>55</sup> while too high volumes can create excessive stiffness in the treated vertebra<sup>61</sup>. Furthermore some authors found no relationship between the amount of bone cement injected and the clinical outcome<sup>5</sup>.

## Results

### *Pain relief and quality of life improvement*

#### *- Immediate and short-term results*

Many clinical studies supported safety and effectiveness of percutaneous vertebroplasty in terms of pain relief and quality of life improvement<sup>31,62-65</sup>.

In a wide literature meta-analysis published in 2006 by Hulme et al. the results reported on 47 papers (about vertebral augmentations performed on 2958 patients) have been compared; pain relief was reported in 87% of patients (1552 pts, 32 studies) in the papers where Visual Analogue Scale (from 0 to 10) was used, VAS score dropped from a mean baseline value of 8.2 (666 pts, 12 studies, 95% CI 7.8–8.6) to a mean post-operative value of 3.0 (95% CI 2.4–3.6)<sup>34</sup>. Pain relief is typically perceived immediately after procedure but in the following days is masked by post-operative pain and postural-adaptive muscular pain thus the optimal pain relief is experienced within a month.

#### *- Long term results*

Even if PMMA has been used in vertebroplasty for more than 20 years there is no scientific evidence of very long term interactions with vertebral cancellous bone and stability of pain relief. There is lack of studies with long term follow up and, currently, no study with follow up longer than 5 years. Is also difficult to gather data for a ten-year follow up as the centers with such a long

experience are very few and furthermore osteoporotic patients have a high mean age (around 75 years old) while patients with bone malignancies have a poor five-year life expectancy.

In the longer available follow-up (5 years) Perez-Higueras et al. reported, despite the limited population, that patients treated with vertebroplasty had a mean VAS score at baseline of  $9.1 \pm 0.6$  (mean $\pm$ SD), that dropped to  $2.1 \pm 1.1$  three days post procedure,  $1.1 \pm 1.1$  after three months and at five years post procedure kept a value of  $2.1 \pm 2.6$  with a prolonged and statistically significant pain relief ( $p < 0.001$ )<sup>66</sup>.

Also in the prospective 3-year follow up study by Voormolen et al. performed on 112 patients treated with vertebroplasty, the clinically significant immediate pain relief was stable at one year and maintained significance on the third year of follow up<sup>67</sup>. In this paper the median baseline VAS score was 9 and dropped initially to a median value of 3 (within 24 hours) kept stable at 3-month (median VAS score: 3) and dropped to a median value of 2 at 6-month, 1-year and 3-year follow up; the same Authors made a literature meta-analysis of 14 similar perspective studies reporting a median baseline VAS score of 7.9 that drops to 2.7 within 24 hours and remains substantially stable (3 and 2.9 respectively) at mid-term (3-6 month) and long-term follow up (1-3 year).

### *- New fractures*

In a wide perspective study performed by Lindsay et al. on 2752 postmenopausal women treated with placebo it was found that among the 381 patients who had a vertebral fracture 19.2% experienced a new fracture within a year (versus a cumulative incidence of 6.6%); thus a patient who already had a vertebral fracture has a 5-fold increased risk to experience a new fracture within a year while the risk becomes 7-fold if there are two collapsed levels <sup>68</sup>.

This “domino effect” makes part of the natural history of osteoporosis and in such a weak equilibrium the influence in the occurrence of new collapses of vertebral augmentation procedures has been long discussed with controversial proofs that percutaneous spine interventions are able to increase, decrease or leave unchanged the risk of new fracture if compared with conservative therapy.

New fractures after percutaneous vertebroplasty are reported in the literature with an incidence ranging from 8% to 52% <sup>69-71</sup> making cause-effect relationship between new fracture, vertebroplasty and underlying osteoporosis controversial. The experimental study by Baroud et al.<sup>72</sup> found an increased discal pressure after stiffening of vertebral fracture due to vertebroplasty leading to a potential higher stress on the endplate of adjacent vertebral bodies.

One of the first studies on the occurrence of new fractures following vertebroplasty was published in 2000 by Grados et al. on 25 patients (out of 40) treated by H. Deramond from 1990 to 1996. These patients underwent physical



and spinal radiological examination in 1997 (mean follow up 48 months  $\pm$ 21 ranging from 12 to 84 months) and in 13 patients (52%, complexively 34 subsequent fractures were found) at least one fracture occurred with a slight but significantly increased risk of vertebral fracture in the vicinity of a cemented vertebra (odds ratio 2.27, 95% confidence interval 1.1-4.56). Pain decreased from  $80 \pm 16$  (VAS score from 0 to 100) to  $37 \pm 24$  at one month and  $37 \pm 28$  at the long term follow up. Only one patient described no improvement in pain after the procedure.

The high incidence of substantially asymptomatic fractures reported in this study may be significantly affected by the small sample size, the high prevalence of secondary osteoporosis (9 pts: 36%), the wide range of follow up and the unknown ongoing medications.

In a perspective study published by Voormolen et al. in 2006<sup>73</sup>, osteoporotic patients treated with percutaneous vertebroplasty (PV) underwent follow-up MRI at 3, 6, and 12 months and 16 out of 66 patients (24%) were found to have 26 new vertebral fractures during the 1 year of follow-up. Most new vertebral compressive fractures (VCFs) occurred within 3 months of PV, half of new VCFs appeared in levels adjacent to treated levels, and half of the new VCFs were symptomatic. In this study, the presence of more than two preexisting VCFs was the only independent risk factor for the development of a new VCF.

In a study published in 2008 by Hierholzer et al.<sup>74</sup> 316 patients were successfully treated (93% with pain relief) with PV for 486 “prevalent

fractures” (with bone marrow edema at MRI) and underwent a clinical follow up by phone interview 1 day, 7 days, 6 months, 1 year and, further on, on a yearly basis after vertebroplasty. In the case of new onset or unsatisfactory relief of back pain, patients were reinvited and physical examination as well as MRI using STIR sequences were performed. During follow-up period (mean follow-up: 8 months; range: 6–56 months) 16.4% of the patients (52 out of 316) returned with 69 symptomatic incidental fractures with bone marrow edema at MRI. In this study, incidental new VCFs were adjacent to previously treated fractures in 51% of cases with no statistically significant difference versus distant VCFs. The most frequent site of new VCFs was thoraco-lumbar junction (cluster: T11-L2) this was both statistically significant for baseline fractures ( $p>0.02$ ) as well as for new fractures ( $p>0.05$ ,  $\chi^2$  test). However, no statistically significant difference in the fracture localization between prevalent and incidental VCFs was found as if anatomy and underlying osteoporosis play a key role in the occurrence of new VCFs.

### ***Complications***

Vertebral augmentation procedure can be currently considered safe as the most recent meta-analysis on vertebroplasty and kyphoplasty found a low morbidity and mortality rate of both procedures<sup>34,75</sup>.

The most serious adverse events can be neurological complications, due to wrong needle pathway and/or PMMA leakage, or pulmonary complications that are mainly due to bone cement venous leakage.

Pulmonary embolism (PE) of bone cement is the most frequent complication, reported from 3.5% to 23%<sup>76</sup>, that in most cases occurs without significant symptoms as PMMA is not thrombogenic and the amount of cement embolized to lungs is too low to determine clinical symptoms. The high rate of PE detected by Kim et al. (23%)<sup>77</sup> in patients undergone vertebroplasty and systematically screened with post-operative chest CT lead to state that the real occurrence of embolic complications is underestimated.

Even if overall morbidity is low, vertebral augmentation procedures can be potentially harmful as among major complication have been described epidural hemorrhage leading to paraplegia<sup>78</sup>, intradural cement leakage<sup>79</sup>, lethal pulmonary embolism<sup>80</sup> and spondylitis<sup>81,82</sup>.

### ***- Vertebroplasty vs placebo***

In 2009 two randomized studies appeared in the New England Medical Journal comparing vertebroplasty with a sham procedure<sup>83,84</sup> concluding that vertebroplasty might have a placebo effect. These papers, published simultaneously in the same important journal cast doubts on a procedure that, since then, was believed to be effective and safe in providing pain relief for symptomatic vertebral fractures. INVEST study, coordinated and published by Kallmes<sup>83</sup>, was a randomized study comparing vertebroplasty (68 patients) versus a control intervention called “sham procedure” (63 patients). Inclusion criteria were painful (VAS>3) osteoporotic vertebral fractures (< 1yr) with one

year follow up. The 131 enrolled patients were blinded to the procedure. The control arm underwent pedicle local anesthesia, and during the “sham procedure” were made to believe they underwent the real vertebroplasty (verbal and physical simulations were made pretending to perform the procedure and the methacrylate monomer was opened to simulate the odor of PMMA mixing). The patients had the chance to cross-over to the other arm after one month and up to three months after the first procedure. The primary clinical outcome was assessed with Roland-Morris Disability Index and perceived pain rated with VAS (0-10) while secondary outcomes were assessed with other questionnaires (Pain Frequency Index, Pain Bothersomeness Index SF 36, SOF-ADL, EQ-5D) and analgesic use; measurements were made at 3 days, two weeks, 1 and 3 months. INVEST study concluded that clinical improvement (at 3 days and 1 month), in patients with painful osteoporotic vertebral fractures, was similar among those treated with vertebroplasty and those treated with a simulated procedure. The study from Kallmes et al. have many drawbacks, first of all the main intent: the “sham procedure” is closer to a facet block than a placebo and doesn't represent the real alternative to vertebroplasty that, in clinical practice, is conservative treatment.

There is a selection bias of such studies because patients with severe pain are unlikely to agree to randomization of a popular intervention versus a fake procedure and there is a further selection bias in this study because, due to the slow recruitment (131 pts enrolled among 1813 screened in 11 sites in US, UK and Australia during a 4-year period), inclusion criteria were broaden even

further to include patients with VAS score of 3. At three months 43% of patients that had undergone the sham procedure had crossed over to vertebroplasty versus 12% of subjects belonging to vertebroplasty arm that had crossed over to the sham arm ( $p < 0.001$ ). “This crossover was the most statistically significant observation in the trial” as stated by Prof. Joshua A. Hirsch in his lecture: “Vertebral Augmentation Procedures in a post RCT world” presented at GRIBOI Meeting 2010 held in Torino (Italy)<sup>85</sup> who furthermore raised concerns about the reliability of patient blinding considering that 74% of patients in control group who guessed correctly (patients were asked to guess which procedure they underwent) and 75% of patients in PV group who guessed incorrectly crossed over to the other group.

Furthermore nor clinical examination nor bone marrow edema on MRI were used for patient selection and during follow up (rather relying on complex questionnaires and plain radiographs) and occurrence of new fractures was not investigated as a possible cause of pain during follow up.

In the “Australian” multicentric randomized controlled study by Buchbinder et al.<sup>84</sup> 78 patients with osteoporotic fractures were recruited (versus 468 screened in 4.5 years and 141 found eligible who declined randomization) and randomly enrolled into the vertebroplasty arm (38 pts) and a placebo arm (40 pts; placebo was represented by a pedicle local anesthesia followed by a 13G vertebroplasty needle placement on periostium). Inclusion criteria were back pain duration less than 12-months and the presence of one or two recent vertebral fractures (edema and/or a fracture line within the vertebral body on MRI were imaging

inclusion criteria).

Primary outcome was overall pain as measured by VAS score (0-10) at 3 months. This study found no significant benefit of vertebroplasty over a sham procedure during 6 months of follow-up among patients with recent osteoporotic vertebral fractures. The Australian trial also showed some flaws such as: the small sample size with possible selection bias, no clinical examination, uncertain MRI inclusion criteria, a very high predominance of one center (67% out of 4 centers, two of them enrolled five patients each) in a so called “multicentric study”. Both the studies were published without any invited commentary and without any pre-procedural and post-procedural imaging.

In this era where only Evidence Based Medicine seems to rule, the simultaneous publication of two randomized controlled trials about the same debated topic on the same world famous journal triggered a chain reaction from media to public opinion and from professional boards to insurance companies.

A bill passed by American Congress in 2009 provided \$1.1 billion for such comparative effectiveness research<sup>86</sup> and these new studies are exactly the kind of research that health policy experts and President Obama government have been calling for to get rid of medical treatments of unproven efficacy.

The news about “vertebroplasty found to be useless for vertebral fractures” was reported by several newspapers, from *New York Times*<sup>87</sup> to *Corriere della Sera*<sup>88</sup>, and internet blogs<sup>89</sup> with opinions that were in some case more critical and in some others categorically agreed with trial conclusions.

This background led some insurance companies<sup>90</sup> to consider denial for reimbursement of vertebroplasty and other vertebral augmentation procedures and some law firms<sup>91</sup> to take advantage of the bad reputation of these interventions to seek patients who want to sue their surgeons for treating them with bone cement. Professional boards and societies took different positions toward percutaneous spinal interventions: American Academy of Orthopaedic Surgeons (AAOS) strongly recommend against vertebroplasty<sup>92</sup> for patients who present with an osteoporotic spinal compression fracture on imaging with correlating clinical signs and symptoms (while accepts kyphoplasty with Strength of Recommendation: Weak) while Society of Interventional Radiology expressed criticism against the trials defending the value of vertebroplasty.<sup>93</sup>

#### ***- Vertebral height increase***

Vertebral body collapse leads to hyperkyphosis which entirely depends upon the number and the severity of wedge fractures. This painful condition can provoke a reduction of the pulmonary function and may lead to further fractures<sup>94,95</sup>.

Based on the background of kyphoplasty an endoprosthesis device has been designed and developed not only to relieve pain but to reduce kyphosis. Vertebroplasty is also able to restore vertebral height<sup>96,97</sup> especially in Kummell's disease and in mobile fractures where is able to obtain a vertebral height gain up to 9.6 mm. Usefulness of height restoration is still debated

because even if vertebral height gain is considered statistically significant in the above cited studies, clinical relevance of kyphosis correction has already to be scientifically proven.

In a small case series from McKiernan et al comparing vertebroplasty with vertebral height restoration (average gain: 2.9 mm. up to 9.6 mm) and without, both groups had a comparable pain relief with no significant difference in terms of quality of life assessed by means of Osteoporosis Quality of Life Questionnaire (OQLQ) <sup>98</sup>. As the authors admit “perhaps the outcome instruments were insensitive to an important clinical benefit of vertebral height restoration that thereby went unrecognized”. Respiratory function improvements were not investigated as usually is in most of studies regarding vertebral augmentation. These results may suggest that questionnaires are inadequate to evaluate clinical relevance of vertebral augmentation rather than invalidate its utility.

#### - *Vertebroplasty and Kyphoplasty vs conservative treatment*

The treatment for osteoporotic spinal compression fracture before spinal interventions were introduced was conservative therapy (bed rest, pain medication, brace support) and, still representing the only current alternative to such treatments, this should be compared to vertebral augmentation procedures rather than a placebo.



Even if considered a safe non-intervention, also conservative treatment also carries some risks, as prolonged bed rest can cause deep vein thrombosis, bone loss (bone density decreases by 2% per week and even more in osteoporotic patients)<sup>99</sup>, decreased cardiac reserve, muscular weakening (muscle strength decreases up to 10%-15% per week)<sup>100</sup> gastrointestinal (reduced appetite and constipation) and respiratory complications (decreased airway clearance and atelectasis with predilection for pneumonia)<sup>101</sup>.

Furthermore the discomfort of brace support and the side effects of opioids must be taken into account in a fragile population such as older female patients. The first perspective non randomized controlled trial of vertebroplasty versus conservative treatment was performed in 2006 by Diamond et al.<sup>102</sup>; this paper compares pain relief in 88 patients that had Vertebroplasty and 38 patients treated conservatively. The vertebroplasty group obtained pain relief that was significant higher than the conservative care group at 24 hours and at 6 weeks; this difference lost significance at 1-year and 2-year follow up. Between the two groups there was no statistically significant difference in new fracture rates.

The main flaw of this study was not to be randomized thus only the few patients who refused vertebroplasty (38 vs 88) were conservatively treated; furthermore the enrolled patients had recent fractures (1-2 weeks) and weren't previously treated with conservative treatment as commonly suggested in vertebroplasty indications. The study by Diamond et al. rather than invalidating the effectiveness of vertebroplasty strengthen the importance to treat patients

when conservative therapy fails as fractures can heal by themselves in the long period. On the other hand, vertebroplasty gifted to a fragile old aged population some pain-free months (up to one year) without the sequelae of prolonged inability and discomfort of brace support

In 2009 Lancet published the 1-year results of the ongoing 2-year follow-up FREE trial<sup>103</sup> and in 2010 the results of VERTOS II<sup>104</sup>; both were multicenter randomized controlled trials comparing conservative treatment respectively to kyphoplasty (FREE) percutaneous vertebroplasty (VERTOS II).

The FREE trial involved 28 sites in 8 European countries enrolling 300 patients that were randomized to kyphoplasty or conservative treatment (149 BKP vs 151 NSM) with a one year follow up (1, 3, 6, 12 month f/u).

Inclusion criteria were 1 to 3 acute VCFs (at least 1 VCF with edema on MRI and one with  $\geq 15\%$  vertebral body height loss), and VAS score  $\geq 4$ .

Conservative Treatment was performed according to hospital protocol with pain medication, bed rest, walking aids, brace support and physiotherapy.

The primary endpoint was to assess the change in SF-36 PCS (Physical Component Summary) at 1 month between the two groups.

Secondary endpoints (at 1, 3, 6 and 12 months) were SF-36 subscales (scale 0–100), EuroQol-5D (EQ-5D) questionnaire, VAS score (0-10), Roland-Morris scale (0-24-point), restricted activity days and bed rest due to back pain in the previous two weeks, analgesic use and adverse events assessment.

This randomized controlled trial showed, with a Level 1 clinical evidence, that in patients with acute symptomatic vertebral fractures, balloon kyphoplasty

improved quality of life, function, mobility, and pain more rapidly than did conservative treatment, with significant differences in improvement between the groups at 1 month. For most outcome measures, the differences between the two groups were diminished at 12 months because the non-surgical group improved over time, probably as a result of fracture healing.

No deaths related to kyphoplasty occurred and BKP showed no difference in frequency of adverse events compared to the non-surgical group.

Kyphoplasty group did not show a significant increase in new radiographic vertebral fractures at 1 year compared with the control group.

Patients in the kyphoplasty group therefore had a better quality of life during the year following the fracture due to faster healing, less narcotic use and quicker return to activity.

The VERTOS II trial involved five large teaching hospitals in the Netherlands and one in Belgium finding 431 patients eligible for participation in the randomized trial (between October 2005 and June 2008), 202 of whom, who had persistent pain, were randomly referred to vertebroplasty (101) or conservative treatment (101). Main inclusion criteria were: vertebral compression fracture (T5 to L5) on spine radiograph (minimum 15% height loss) with bone marrow edema on MRI, VAS  $\geq 5$ , focal tenderness at fracture level, and decreased bone density (T scores  $\leq -1$ ).

The primary outcome was pain relief at 1 month and 1 year, measured with a VAS score (0-10) while the secondary outcome was cost-effectiveness at 1 month and 1 year and the tertiary outcome was quality of life measured with

QUALEFFO questionnaire<sup>105</sup> and physical function measured with the Roland Morris Disability questionnaire.

Vertebroplasty provided a greater pain relief compared to conservative treatment; difference in mean VAS score between baseline and one month was -5.2 after vertebroplasty and -2.7 after conservative treatment, and between baseline and one year was -5.7 after vertebroplasty and -3.7 after conservative treatment. The difference between groups in reduction of mean VAS score from baseline was 2.6 at one month and 2 at one year.

It is noteworthy that more than half of the patients who initially qualified for the study had a spontaneous decrease of the perceived pain with a VAS score lower than 5 thereby precluding inclusion. In conclusion, in a selected subgroup of patients with acute osteoporotic vertebral fractures and persistent pain (unresponsive to initial conservative management) vertebroplasty has shown to be effective and safe providing immediate and durable pain relief.

# Vertebral augmentation with nitinol endoprosthesis: clinical experience with one year follow up in 40 patients

## **Aim**

To assess safety, effectiveness and vertebral height restoration of endoprosthesis-assisted vertebroplasty during long-term follow-up

## **Materials and Methods**

Between December 2008 and September 2009, 40 consecutive patients (36 females, mean age  $73.6 \pm 8$  years, range: 55-86 years,) were treated with percutaneous vertebral augmentation performed by placement of 84 nitinol prostheses (two devices were positioned in each vertebra and 2 patients were treated for two fractures in the same session).

### **- *Patient selection***

A pre-procedural consultation was arranged with all patients in order to perform a physical examination, to gather imaging and anamnestic issues useful to find a correlation between symptoms, history and imaging findings, and to explain benefits and risks of vertebral augmentation.

*Inclusion criteria were as follows:*

- 55 years or older
- A1.1, A1.2 or A1.3 compression fractures according Magerl's A.O Fracture Classification
- Bone marrow edema within the fracture assessed with MRI (performed with fat suppression sequences)
- Significant back pain (Visual Analogue Scale score: 5 or higher)
- Tenderness to palpation over the spinous process of the fractured vertebra
- Minimum of 4 weeks of conservative treatment (bed rest, brace support,, analgesic therapy)

*Exclusion criteria were as follows:*

- A2, A3, B and C vertebral fractures according Magerl's A.O. Fracture Classification
- Systemic infection or any suspicious infective spondylodiscitis
- Uncorrectable coagulation disorders
- Healed fractures without bone marrow edema
- Unspecific or mild back pain (VAS: 4 or lower)
- Nerve root pain or neurologic deficit due to the fracture
- Poor general conditions (Karnofsky score < 50%, ECOG >3)

- *Technique*

All interventions were performed in the angiographic room equipped with machinery capable of both fluoroscopy and CT-like multiplanar reconstructions obtained by acquiring the desired body volume with rotation of the C-arm working as a cone beam CT (Allura Xper CT; Philips).(Fig. 1e)

Monitoring of patient's heart rate and pulse oximetry were carried out continuously throughout the procedure and blood pressure was monitored externally and recorded automatically every 5 minutes. Continuous assistance to the patient was offered during the procedure by a trained nurse. When necessary the patients were asked by the interventional radiologist about the features of perceived pain (eventual nerve shock sensations) and sensitivity and mobility of lower limbs in order to further rule out nerve damage.

All procedures were performed with local anesthesia by injection of no more than 1.5mL of 2% Lidocaine hydrochloride (Lidosan, Industria Farmaceutica Galenica Senese, Monteroni d'Arbia, Siena, Italy) per needle administered subcutaneously and over pedicle periostium. Lidocaine was administered using a 22 G quincke needle positioned under fluoroscopic guidance in "the eye of the Scottie dog" for lumbar levels or through the costotrasversary joint for thoracic levels following the desired transpedicular or costotrasversary path of the vertebroplasty needle. Access needles were inserted using the described radiologic landmarks in the oblique projection and

then advanced in the Antero-Posterior projection in order to reach the medial aspect of the pedicle.

A CT scan was then performed in order to assess the correct needle path and to measure pre-procedural vertebral height. (Fig. 1c, 3c, 3d) When the needles were in the correct position, the pathway for the implant was created using a coaxial manual drill (Fig. 1d).

Bone tissue removed during drilling was gathered for histological examination as a coaxial tru-cut biopsy is routinely performed in all bone interventions at our institution, to determine underlying pathologies, including malignancies.

The implant delivery systems (SpineAlign VerteLift™ System; San Jose, CA, USA) were then introduced through the cannula and the nitinol implants were manually opened using the handle attached to the delivery system (Fig. 2e) and adjusted under fluoroscopy until an “XX” fashion in the AP projection was obtained (Fig. 2b, 2d) in order to allow device struts to lift the vertebral endplates and restore vertebral height.

Once the implants were properly positioned and fully expanded, the delivery system was detached. (Fig 2c, 2d)

Injection cannulae were pre-filled with polymethylmethacrylate (PMMA; KyphX HV-R®; Elmdown LTD. London, England) and, when bone cement reached a “toothpaste consistency”, were coaxially advanced through the working cannulae up to the distal end of the implant. Cement injection was



performed, under continuous fluoroscopic guidance, emptying the prefilled cannulae with a manual blunt tip pusher. (Fig. 3g)

An average amount of 5 mL of thickened PMMA was injected per level; injection was stopped when a satisfactory vertebral replenishment was obtained, or in case of significant leakage.

Once the injection was over and the needles withdrawn, a CT scan was performed in order to repeat vertebral measurements, rule out complications and detect any leakage. (Fig 3e, 3f)

#### - *Device*

The endovertebral prosthesis used in this study was a Nitinol cage (VerteLift™, SpineAlign Inc. San Jose, CA USA). Nitinol is a proven biocompatible Nickel-Titanium alloy commonly used in interventional radiology for decades which has a unique combination of shape memory and super-elasticity properties.

The implant struts are designed to flex against endplates and obtain a broad pressure distribution, without a single point contact, thus avoiding endplate damage. Nitinol returns to its original shape after repeated, large deformations and the VerteLift™ implant showed resistance to subsidence demonstrated at 3000N for five million cycles with a static compression that resulted in 4-fold to 5-fold greater than the maximum physiologic loads.

Pressure exerted in biomechanical tests by an asymmetric 18 mm VerteLift implant was 3.3 MPa, thus strong enough to shift endplates (pressure to shift

healthy bone is 2.5MPa while pressure to shift osteoporotic bone is 1.25MPa) and significantly below the pressure level required to fracture an endplate (pressure to fracture healthy bone is around 8MPa while pressure to fracture osteoporotic bone is around 4MPa).

The VerteLift implant is designed to be collapsed and expanded multiple times, if repositioning is required, and can also be safely retrieved and withdrawn through the cannula (also when completely expanded and released) if removal is necessary.

The implants used in the study were in asymmetric and symmetric shapes with 16 mm and 18 mm diameters (identical to commercially available ones, currently available also in 14 mm and 20 mm sizes).

The implant size and shape chosen were based on fracture shape and vertebral body size; a given implant could be replaced with a different size or shape, even after expanding in the vertebral body, if it did not fit the vertebral fracture that was being treated.

The nitinol implant is mounted on a delivery system that allows, in the closed fashion, its insertion through the 4.8 mm working cannula and through the channel made with the manual drill inside the vertebral body. The delivery system is mounted on a handle (the one used in our experience was the “amber” reusable prototype) that, with a simple manual screw/rotate/unscrew mechanism allows opening, positioning and closing of the prosthesis.

The VerteLift System for vertebral augmentation included an access kit (two 4.8 mm needles/working cannulas with beveled tip and a manual drill) and

some injection cannulae with tapered ends designed to be inserted in the working cannulae and through the implant up to its distal part. Blunt tip pushers of two different sizes were also included to empty both the large proximal part and the tapered distal end thus delivering approximately 1.6cc of bone cement per cannula.

- ***Radiological assessment and vertebral height measurements***

Vertebral height was measured immediately before and after vertebral augmentation in order to assess vertebral height restoration.

For pre-procedural and post-procedural measurements, CT-like multiplanar reconstructions were obtained by the angiographic equipment.

Six measurements were taken for each treated level: three in the mid-coronal reconstruction (left, central and right) and three in the mid-sagittal reconstruction (anterior, central and posterior).

A standard CT scan (LightSpeed16; General Electric. Milwaukee, U.S.A.) was performed one year after the procedure to check implant position and integrity and to repeat measurements with MPR reconstructions (Advantagewin 4.2; General Electirc). CT scan field of view included one level above and one below the treated fractures.

On the same day a standing plain radiogram of the spine was taken to assess spine alignment, fracture stability and new fractures on the thoracolumbar spine.

All of the CT measurements and plain film evaluations were made by two independent radiologists blinded to clinical outcomes.

- ***Pain and Quality of life assessment***

Patients were asked to rate their perceived pain using a visual analog scale (VAS) on a 0-10 scale at baseline (the day of the intervention), after the procedure (within 24 hours) and after one year. A VAS score post-procedural reduction of at least 2 points was considered significant.

Analgesic drug use was rated from 0 to 4 as follows: 0 for no drugs, 1 for Non-Steroidal Anti-Inflammatory Drugs (NSAID), 2 for oral narcotics, 3 for transdermal opioids, 4 if opioids were administered intravenously.

Quality of Life (QoL) was assessed using the Oswestry Disability Index (ODI) questionnaire at the time of clinical interview before the procedure, two weeks after the procedure and one year after the procedure.

- ***Statistic analysis***

Raw data for CT measurements, VAS scores, and ODI scores performed at baseline, immediately after the procedure and at the one year follow ups were analyzed with InStat 3 software (GraphPad;, San Diego, CA-USA) designed for Mac.

## Results

All VerteLift™ implants were successfully positioned in all patients. No major complications or peri-operative deaths occurred. No venous PMMA bone cement leakages were detected with fluoroscopy during the procedure or with post-procedural CT scans.

Mild asymptomatic cement leakages were detected in four out of 42 treated levels: one was para-pedicular and three were inside the vertebral disc. The overall leakage rate was 9.5% while discal and venous leakage rate were 7.1% and 0% respectively.

Vertebral height was significantly increased (restored) ( $p < 0.0001$  paired t-test) at immediate post-operative measurements: average height gain (millimeters) in mid-coronal MPR reconstruction were  $2.4 \pm 2.4$  (left),  $3.9 \pm 3.0$  (center),  $1.6 \pm 1.9$  (right) and in mid-sagittal MPR reconstruction were  $2.3 \pm 2.3$  (anterior),  $4.7 \pm 3.6$  (center) and  $1.9 \pm 2.2$  (posterior) (very significant  $p = 0.0026$ ).

Perceived back pain reduced from a baseline value of  $8.0 \pm 1.6$  SD to a mean VAS score of  $0.7 \pm 1.4$  SD within 24 hours, obtaining a mean differential VAS score of  $7.3 \pm 1.7$  SD that was statistically significant ( $p < 0.0001$ , Wilcoxon test). Immediate pain relief was obtained in all patients but one (patient # 30) with an overall pain improvement of 97.5% within 24 hours.

Oswestry Disability Index (ODI) had a mean value of  $6.5\% \pm 13.7\%$  SD two weeks after the procedure versus a baseline mean value of  $69.7\% \pm 16\%$  SD

with a differential mean value of  $63.2\% \pm 18.4\%$  SD. Quality of life had a statistically significant improvement at short term follow up ( $p < 0.0001$ , Wilcoxon test).

Patients were thereafter contacted by phone in order to arrange a clinical evaluation (with VAS and ODI assessment) and a radiological evaluation (standing plain radiogram of the spine and spine CT). Mean follow up was 15 months  $\pm 2.0$ , ranging from 11 to 21 months.

Follow up has been completed in 38 of the 40 (95%) patients. One patient (#30) who had undergone vertebral augmentation on L5 with incomplete pain relief, required surgical fixation for an underlying mild lysis and therefore did not complete the follow up. One patient (#22) died after six months for heart failure, thus no deaths related to the procedure occurred during follow up.

ODI obtained at baseline, at 15 days and at 1-year follow up and VAS scores at baseline, within 24 hours and at 1-year follow up were compared with Dunn's Multiple Comparisons Test.

A statistically significant difference was confirmed between pre-procedural and post-procedural ODI and VAS scores. The difference between pre-procedural and 1-year follow up values were also significantly different. The difference between post-procedural and 1-year follow up pain relief and quality of life scores were not significant thus meaning that benefits provided by vertebral augmentation were long-lasting and stable.

In Dunn's Multiple Comparison Test, if the difference between rank sum means is greater than 21.420 the p value is considered less than 0.05.

P value >0.05 was considered not statistically significant.

P-value <0.01 and p-value <0.001 were considered, respectively, significant and extremely significant. Rank sum differences and corresponding p-values for each measurement are summarized in the tables below.

*Oswestry Disability Index*

Comparison	Rank Sum Difference	p-value
ODI pre-op vs. post-op	59.000	p<0.001
ODI pre-op vs. 1 year	53.500	p<0.001
ODI post-op vs. 1 year	-5.500	p>0.05

*Visual Analogue Scale*

Comparison	Rank Sum Difference	p-value
VAS pre-op vs. post-op	59.000	p<0.001
VAS pre-op vs. 1 year	53.500	p<0.001
VAS post-op vs. 1 year	-5.500	p>0.05

Pre-procedural, post-procedural and long term follow up CT measurements were compared with Dunn's Multiple Comparisons Test concluding that there is a statistically significant difference between all pre-procedural and post-procedural measurements, between all pre-procedural and long-term follow up measurements while there is no statistically significant difference between any post-operative and long-term follow up measurements. These data lead to our conclusion that we obtained significant increases in vertebral height that were substantially stable over the reported time periods, with no significant height loss during long term follow up. Rank sum differences and corresponding p-values for each measurement are summarized in the tables below.

*Vertebral height measurements in MPR Mid-Coronal reconstruction:*

Comparison ( <i>see table 3</i> )	Rank Sum Difference	p-value
Left pre-op vs. left post-op	-37.000	p<0.001
Left pre-op vs. left 1 year	-32.000	p<0.01
Left post-op vs. left 1 year	5.000	p>0.05

Comparison ( <i>see table 4</i> )	Rank Sum Diff.	p-value
Center pre-op vs. center post-op	-56.000	p<0.001
Center pre-op vs. center 1 year	-52.000	p<0.001
Center post vs. center 1 year	4.000	p>0.05



Comparison ( <i>see table 5</i> )	Rank Sum Diff.	p-value
Right pre-op vs. right post-op	-35.500	p<0.001
Right pre-op vs. right 1 year	-36.500	p<0.001
Right post-op vs. right 1 year	-1.000	p>0.05

*Vertebral height measurements in MPR Mid-Sagittal reconstruction:*

Comparison ( <i>see table 6</i> )	Rank Sum Diff.	p-value
Anterior pre-op vs. ant post-op	-35.500	p<0.001
Anterior pre-op vs. ant 1 year	-39.500	p<0.001
Anterior post-op vs. ant 1 year	-4.000	p>0.05

Comparison ( <i>see table 7</i> )	Rank Sum Diff.	p-value
Center pre-op vs. center post-op	-55.000	p<0.001
Center pre-op vs. center 1 year	-47.000	p<0.001
Center post-op vs. center 1 year	8.000	p>0.05

Comparison ( <i>see table 8</i> )	Rank Sum Diff.	p-value
Posterior pre-op vs. poster. post-op	-34.500	p<0.001
Posterior pre-op vs. poster. 1 year	-30.000	p<0.01
Posterior post-op vs. poster. 1 year	-4.500	p>0.05

During follow-up no device change or migration was observed.

In follow-up, six patients had new fractures with an overall fracture rate of 15% but as pt. # 2 had an high energy trauma (fell from the stairs) two weeks after vertebral augmentation and pt. #19 was found to have an underlying Multiple Myeloma (after biopsy) only four must be considered as spontaneous osteoporotic new fractures with a new fracture rate of 10%. Three fractures were detected on the levels above the treated vertebra (all spontaneous) and three on the level below the treated vertebra (including one spontaneous, one traumatic and one in the patient with myeloma).

VerteLift didn't show any significant artifact at MRI (patient #23 performed MRI at 1-year ). (Image 4)

## Discussion

Vertebral augmentation performed with the VerteLift implants was safe as no major complications related to the procedure occurred during the intervention and at 1-year follow up. VerteLift implant was retrievable and repositionable whenever necessary and the 84 implanted devices exhibited no change in position or morphology over a follow up period up to 21 months.

There is lack of published data about vertebral implants but occurrence of implant migration is not likely to happen as, despite the few cases performed worldwide, a single adverse event was reported in FDA MAUDE database for delayed migration of a Staxx FX (Spine Wave, Shelton, CT, USA) three months after intervention causing back pain and requiring surgery<sup>106</sup>.

As routine vertebral augmentation is designed to be entirely performed with a percutaneous access, and a large number of these interventions are performed by interventional radiologists, an important goal is to minimize complications requiring surgical revision as a result of failed detachment of the device and malpositioning or migration of the implant.

The VerteLift procedure was demonstrated to be safe in terms of venous leakages. In our experience venous cement leakage never occurred. This indicates that is possible to obtain vertebral augmentation with an optimal safety profile and predictable low cement leakage without compacting cancellous bone.

This method of vertebral augmentation was extremely effective in terms of immediate pain relief and quality of life improvement for patients following vertebral compression fractures considering that mean pre-op/post-op VAS and difference was  $7.3 \pm 1.3$  and the mean ODI difference between pre-operative value and 2-weeks follow up was  $-63.2\% \pm 18.4\%$ . The improvements in VAS and ODI scores, both clinically significant, didn't show statistically significant changes over one-year follow up period thus meaning that a durable reduction of symptoms was achieved.

Vertebral augmentation performed with VerteLift has demonstrated safety and effectiveness (in terms of pain relief and QoL improvement), which constituted the main endpoints of this study. These results are comparable with traditional vertebral augmentation procedures such as vertebroplasty and balloon kyphoplasty.

The Nitinol VerteLift implant has the theoretical advantage to prevent loss of vertebral height intraoperatively and post-operatively over time by exerting an endplate to endplate lifting that is sustained during bone cement injection and is permanently maintained after polymerization while in kyphoplasty, the vertebral height restored during augmentation, can be lost after balloon deflation due to elastic recoil.

In this study, most of the restored vertebral height was measured in the central point of the endplates. Highest gains were found in the central measurement taken in mid-coronal ( $3.9 \text{ mm} \pm 3.0 \text{ SD}$ ) and in mid-sagittal reconstruction ( $4.7 \text{ mm} \pm 3.6 \text{ SD}$ ).

Vertebral height restoration was kept stable by the cemented nitinol implant. No statistically significant height loss, in any of the six anatomic measuring points was detected during one-year follow-up measurements. Height loss could be an issue in other vertebral augmentation procedures as both in kyphoplasty<sup>107</sup> and vertebroplasty<sup>108</sup> have already been reported in the literature.

A comparative trial involving balloon kyphoplasty and a metallic implant made of titanium (OsseoFix™, Alphatec Spine Inc., Carlsbad, CA, USA)<sup>109</sup> was performed in a biomechanical *in vitro* study. Significantly greater vertebral height loss ( $P < 0.025$ ) was detected after recompression of kyphoplasty repair ( $0.29 \pm 0.12$  cm versus  $0.20 \pm 0.11$  cm) compared to the titanium mesh implant. The biomechanical properties (yield load, ultimate load and stiffness) of the two repair techniques were not found to be statistically different while the amount of bone cement required for the OsseoFix procedure was less than for kyphoplasty and cancellous bone was more likely to be preserved as 4 of 48 repaired vertebrae demonstrated significant damage by the Kyphoplasty balloon procedure.

The VerteLift implant, compared to OsseoFix, should provide endplate-to-endplate lifting with potential greater height restoration, lower height loss over time with the additional significant value of complete retrievability and ability to be repositioned as often as necessary to achieve optimal vertebral reconstruction.

Compared to kyphoplasty the placement of nitinol implant provided vertebral height restoring partially preserving cancellous bone; cement interdigitation through trabeculae therefore allowed to inject an average amount of 5 mL PMMA instead of the 8 mL required to fill the cavity created by two 4cc kyphoplasty bone tamps. This was an important feature as the amount and the distribution of bone cement has a significant correlation with the incidence of a subsequent vertebral fracture<sup>110</sup>

The incidence of new spontaneous vertebral fractures was 10% (the post-traumatic high energy fracture and the fracture in the patient found with an underlying Myeloma were excluded) that can't be compared with statistical significance with conservative treatment or any other procedure as we didn't have any control group but this percentage lays in the low values of the range shown by other vertebral augmentation procedures.

## **Conclusion**

Vertebral augmentation performed with the VerteLift nitinol implant is a safe and effective procedure able to provide a long-lasting pain relief and a persistent vertebral height gain. Furthermore the nitinol implant allowed to obtain an optimal trabecular perfusion of bone cement, due to preservation of cancellous bone, without the occurrence of venous leakages.

## Tables and Images

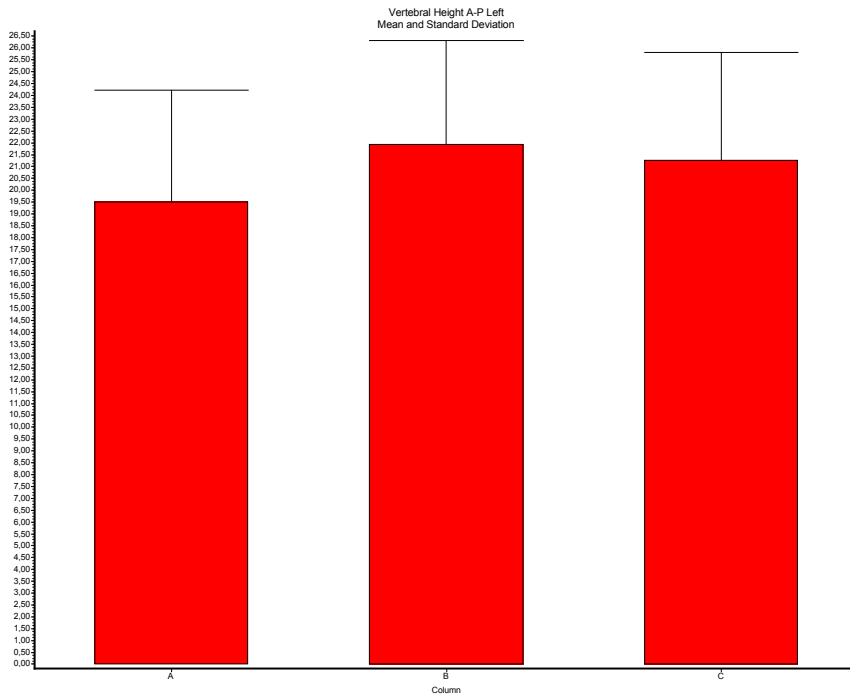
#	Pt	Sex	Age	Diagnosis	Treated Vt	Magerl Class	N° Tot	VAS Pre	VAS Post	VAS Diff	VAS 1-y	VAS diff 1-y	Pain Relief	Analg Before	Analg After	Brace Before	Brace After
1	S.M.	F	76	Osteoporosis	L3	A1.3	1	10	0	10	3	7	Y	3	0	1	0
2	G.L.	F	62	Osteoporosis	L2	A1.1	1	6	0	6	0	6	Y	1	0	1	0
3	L.V.	F	65	Osteoporosis	L2	A1.3	1	9	2	7	1	8	Y	1	0	1	0
4	G.F.	F	68	Osteoporosis	D12	A1.1	1	7	0	7	1	6	Y	1	0	1	0
5	P.A.M.	F	78	Osteoporosis	D12	A1.1	1	5	0	5	0	5	Y	1	0	0	0
6	P.A.	F	64	Osteoporosis	D11	A1.1	1	9	0	9	3	6	Y	1	0	1	0
7	G.M.	M	55	Trauma	L4	A1.3	1	5	0	5	0	5	Y	1	0	1	0
8	F.G.	F	78	Osteoporosis	L2	A1.1	1	6	0	6	0	6	Y	1	0	1	0
9	B.B.	F	77	Osteoporosis	L3 L4	A1.3 A1.3	2	8	2	6	0	8	Y	1	0	0	0
10	A.L.	F	72	Osteoporosis	D11	A1.1	1	7	1	6	2	5	Y	1	0	0	0
11	M.A.	M	55	Trauma	L1	A1.1	1	7	0	7	0	7	Y	1	0	0	0
12	B.M.	F	84	Osteoporosis	D12	A1.3	1	8	1	7	1	7	Y	1	0	1	0
13	M.G.	F	78	Osteoporosis	D12	A1.2	1	9	1	8	1	8	Y	1	0	1	0
14	A.G.	F	67	Osteoporosis	D12	A1.1	1	6	0	6	0	6	Y	1	0	0	0
15	F.C.	F	73	Osteoporosis	L1	A1.1	1	9	0	9	0	9	Y	1	0	1	0
16	P.Co	M	74	Osteoporosis	L3	A1.1	1	6	0	6	1	5	Y	1	0	0	0
17	P.Ci	F	77	Osteoporosis	L3	A1.3	1	6	0	6	0	6	Y	1	0	1	0
18	M.M.	F	80	Sec. Osteoporosis	L4	A1.1	1	8	0	8	8	0	Y	1	1	1	0
19	A.A.V.	F	73	Myeloma	L1	A1.3	1	9	1	8	4	5	Y	1	0	0	0
20	S.M.	F	85	Osteoporosis	D12	A1.2	1	9	2	7	1	8	Y	1	0	1	0

**Table 1:** Patients demographics (pt # 1 to 20), VAS (Pre-, Post-op, 1 year), Pain relief Brace and Analgesic use (Pre- and follow up)

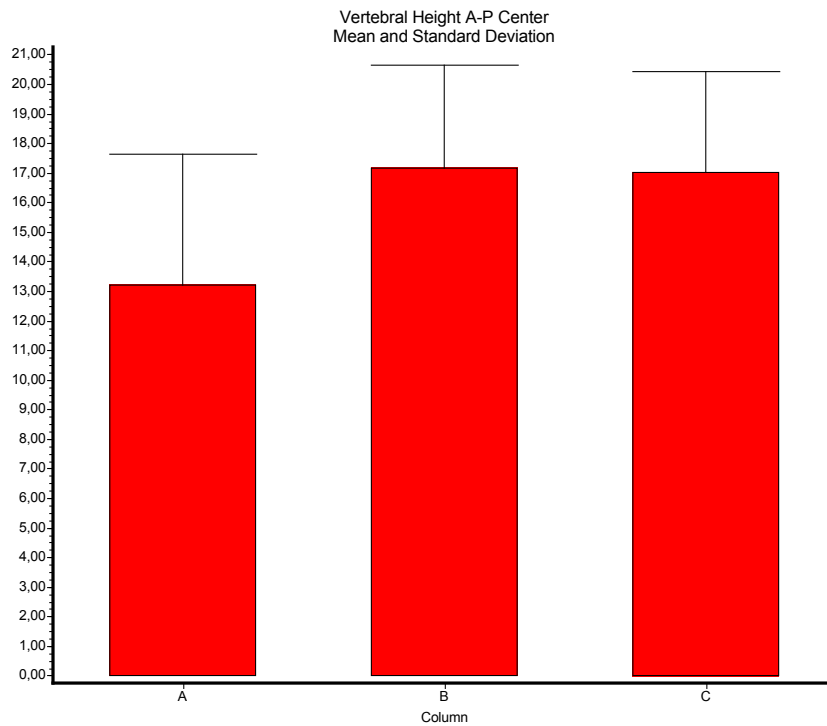
#	Pt	Sex	Age	Diagnosis	Treated Vt	Magerl Class	N° Tot	VAS Pre	VAS Post	VAS Diff	VAS 1-y	VAS diff 1-y	Pain Relief	Analg Before	Analg After	Brace Before	Brace After
21	G.R.C.	F	86	Osteoporosis	D12	A1.1	1	8	0	8	5	3	Y	1	0	1	0
22	B.S.	F	67	Osteoporosis	L2	A1.1	1	8	0	8	-	-	Y	1	0	1	0
23	A.C.A.	F	63	Osteoporosis	D12	A1.2	1	9	1	8	1	8	Y	1	0	0	0
24	M.C.	F	67	Osteoporosis	D11	A1.2	1	5	0	5	0	5	Y	1	0	1	0
25	C.B.	F	78	Osteoporosis	L1	A1.1	1	10	1	9	1	9	Y	3	0	1	0
26	B.A.	F	81	Osteoporosis	D12	A1.2	1	9	1	8	3	6	Y	1	0	1	0
27	F.C.M.	F	70	Osteoporosis	L2	A1.1	1	8	0	8	0	8	Y	1	0	1	0
28	C.S.	F	72	Sec. Osteoporosis	L4	A1.3	1	10	2	8	1	9	Y	3	0	1	0
29	M.R.	F	65	Osteoporosis	D11	A1.2	1	10	0	10	1	9	Y	1	0	1	0
30	M.L.	F	66	Osteoporosis	L5	A1.3	1	10	8	2	-	-	N	1	1	1	1
31	V.M.L.	F	85	Osteoporosis	D12	A1.2	1	10	0	10	0	10	Y	3	0	1	0
32	C.B.	F	85	Osteoporosis	L1	A1.2	1	10	1	9	1	9	Y	3	0	1	0
33	C.A.	F	76	Osteoporosis	D12	A1.2	1	8	0	8	0	8	Y	1	0	1	0
34	D.R.	F	80	Osteoporosis	L3	A1.3	1	10	1	9	1	9	Y	1	0	1	0
35	S.L.	F	74	Osteoporosis	L3	A1.1	1	7	0	7	0	7	Y	1	0	1	0
36	V.R.	F	82	Osteoporosis	L1	A1.3	1	7	0	7	0	7	Y	1	0	1	0
37	C.Be	F	83	Osteoporosis	L1	A1.1	2	8	1	7	0	8	Y	3	0	1	0
38	M.I.	F	60	Osteoporosis	L2	A1.2	1	7	0	7	0	7	Y	1	0	1	0
39	C.Br.	F	83	Osteoporosis	L1	A1.3	1	10	0	10	0	10	Y	3	0	1	0
40	G.A	M	81	Osteoporosis	L4	A1.3	1	5	0	5	0	5	Y	1	0	0	0

**Table 2:** Patients demographics (pt # 21 to 40), VAS (Pre-, Post-op, 1 year), Pain relief Brace and Analgesic use (Pre- and follow up)

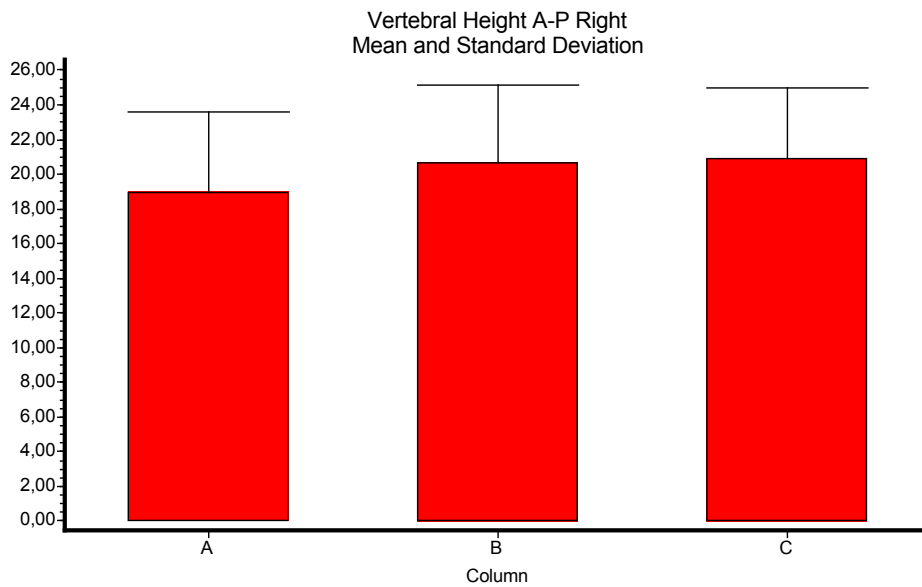




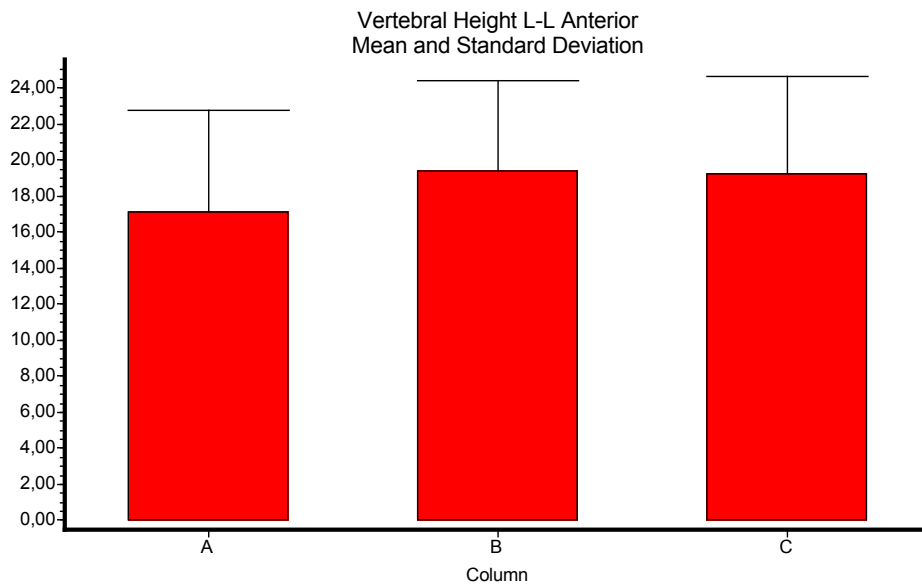
**Table 3:** Left Vertebral height measurements in MPR Mid-Coronal reconstruction. Pre-op, post-op, 1-y



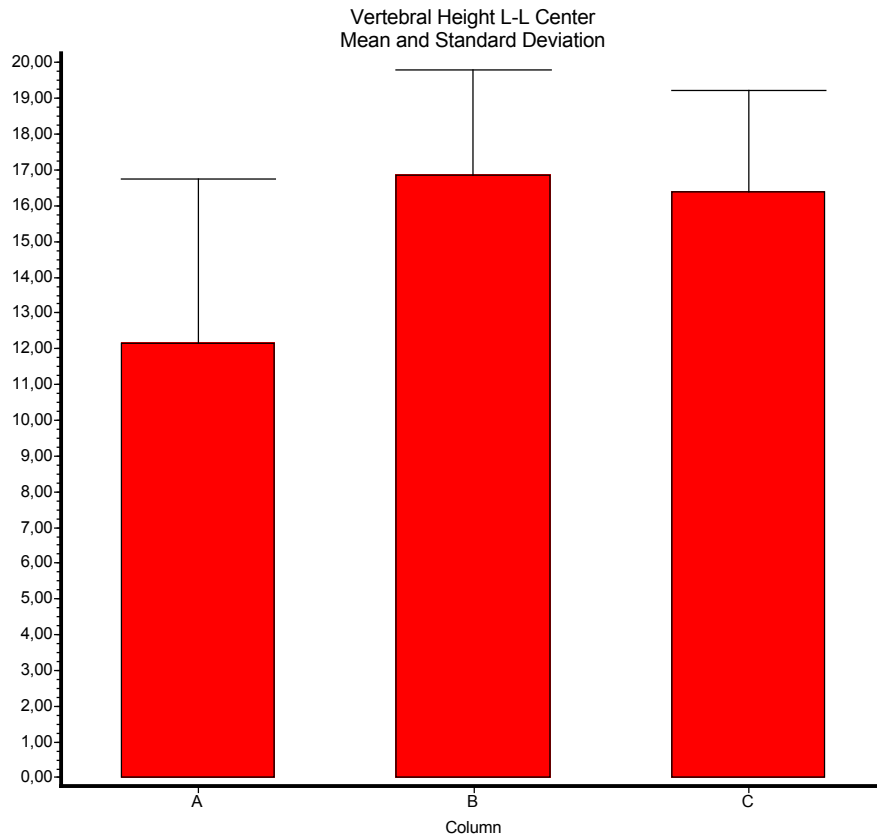
**Table 4:** Center Vertebral height measurements in MPR Mid-Coronal reconstruction. Pre-op, post-op, 1-y



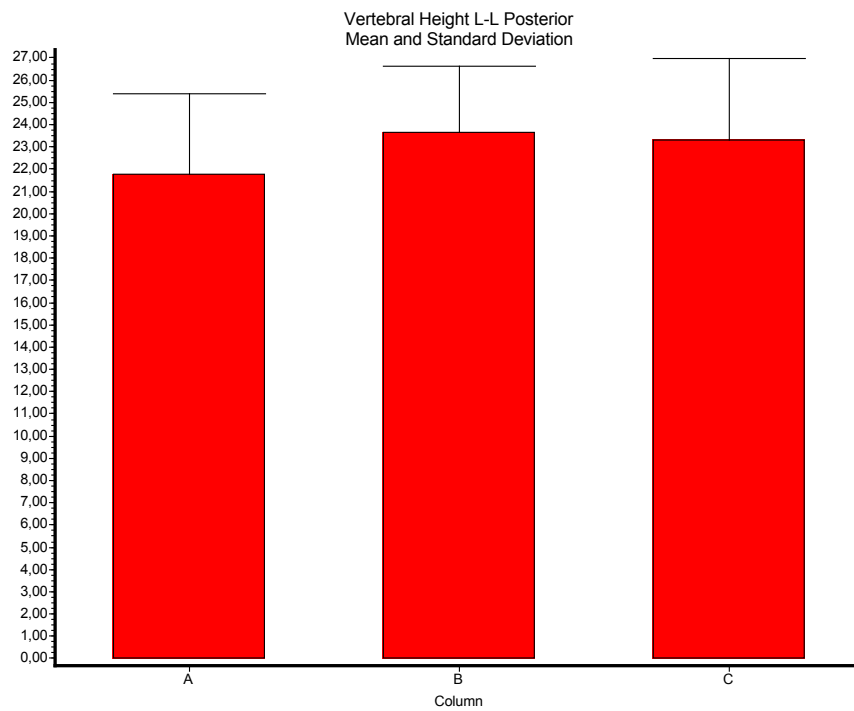
**Table 5:** Right Vertebral height measurements in MPR Mid-Coronal reconstruction. Pre-op, post-op, 1-y



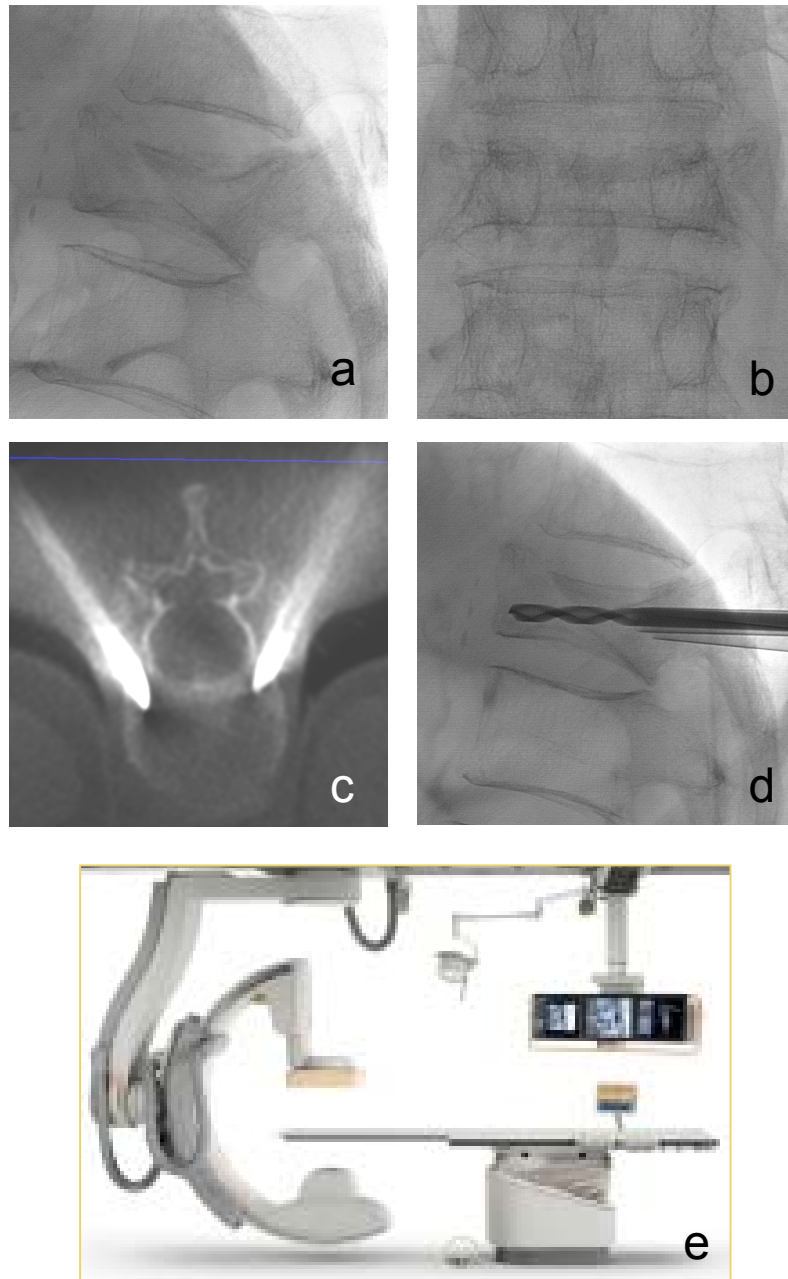
**Table 6:** Anterior Vertebral height measurements in MPR Mid-Sagittal reconstruction. Pre-op, post-op, 1-y



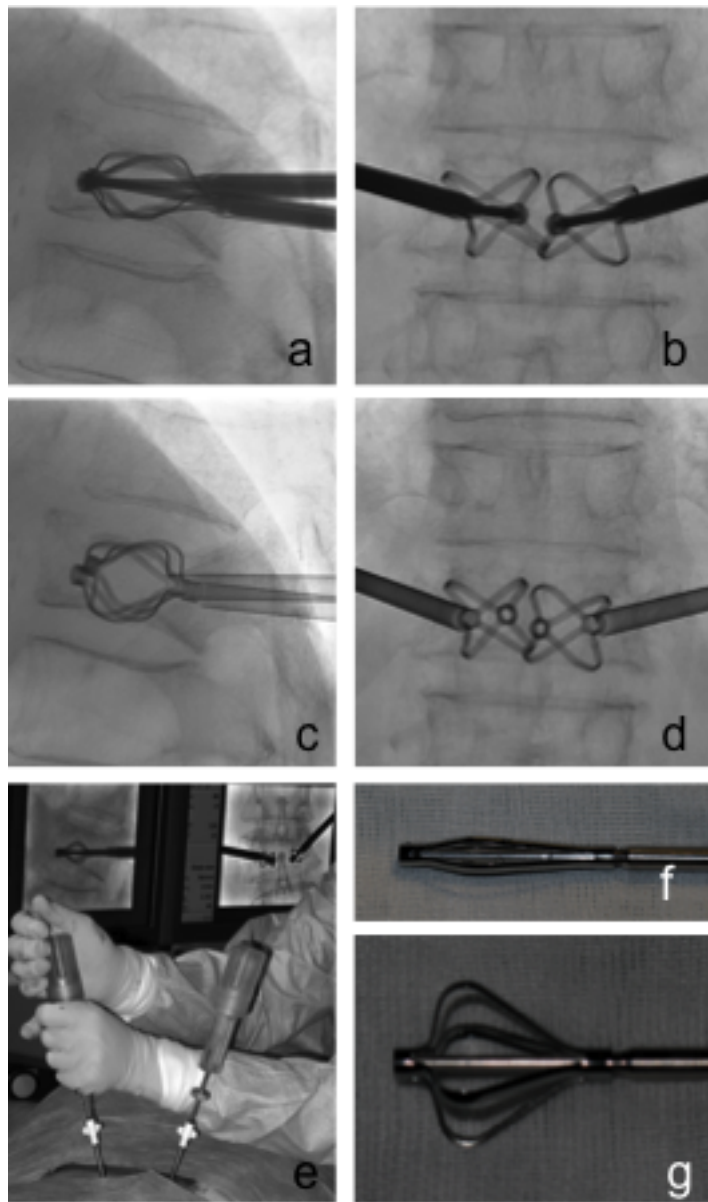
**Table 7:** Center Vertebral height measurements in MPR Mid-Sagittal reconstruction. Pre-op, post-op, 1-y



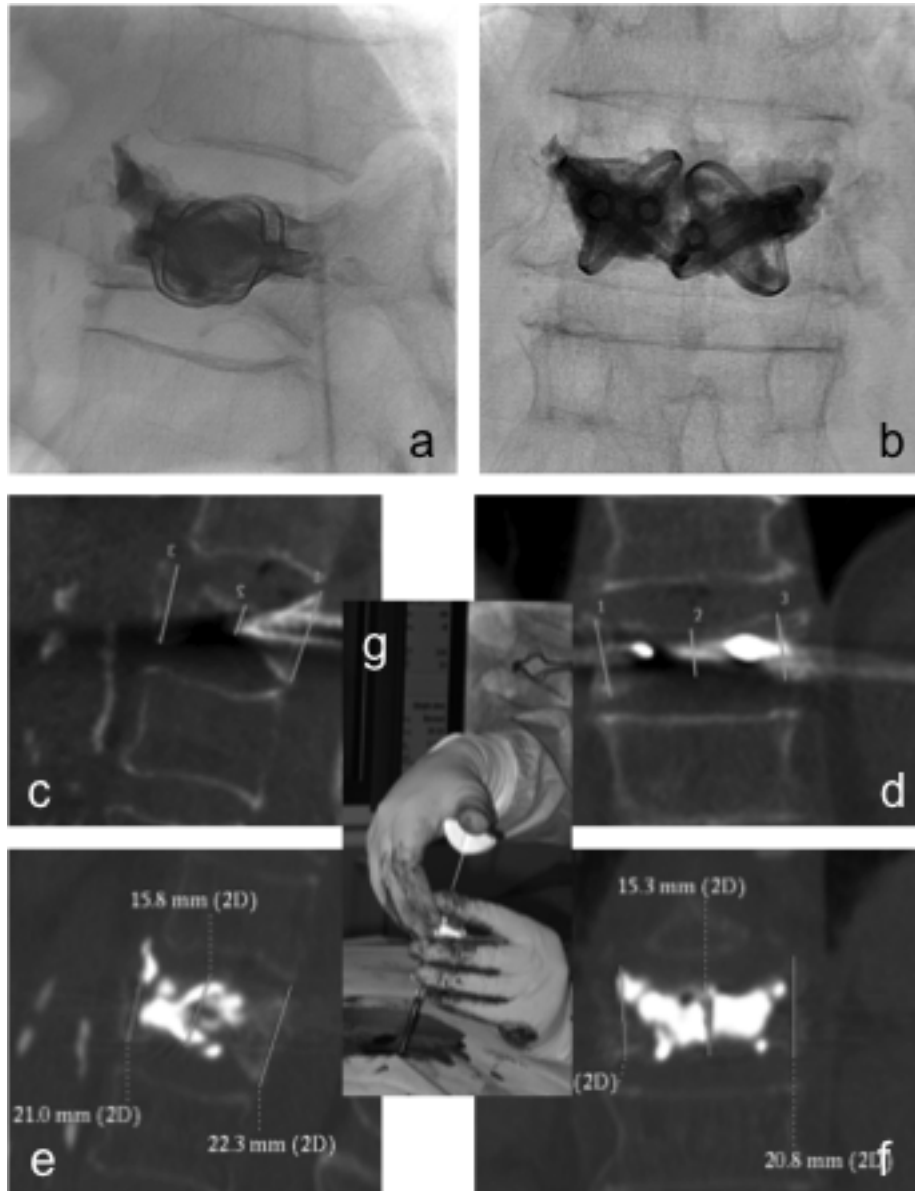
**Table 8:** Posterior Vertebral height measurements in MPR Mid-Sagittal reconstruction. Pre-op, post-op,



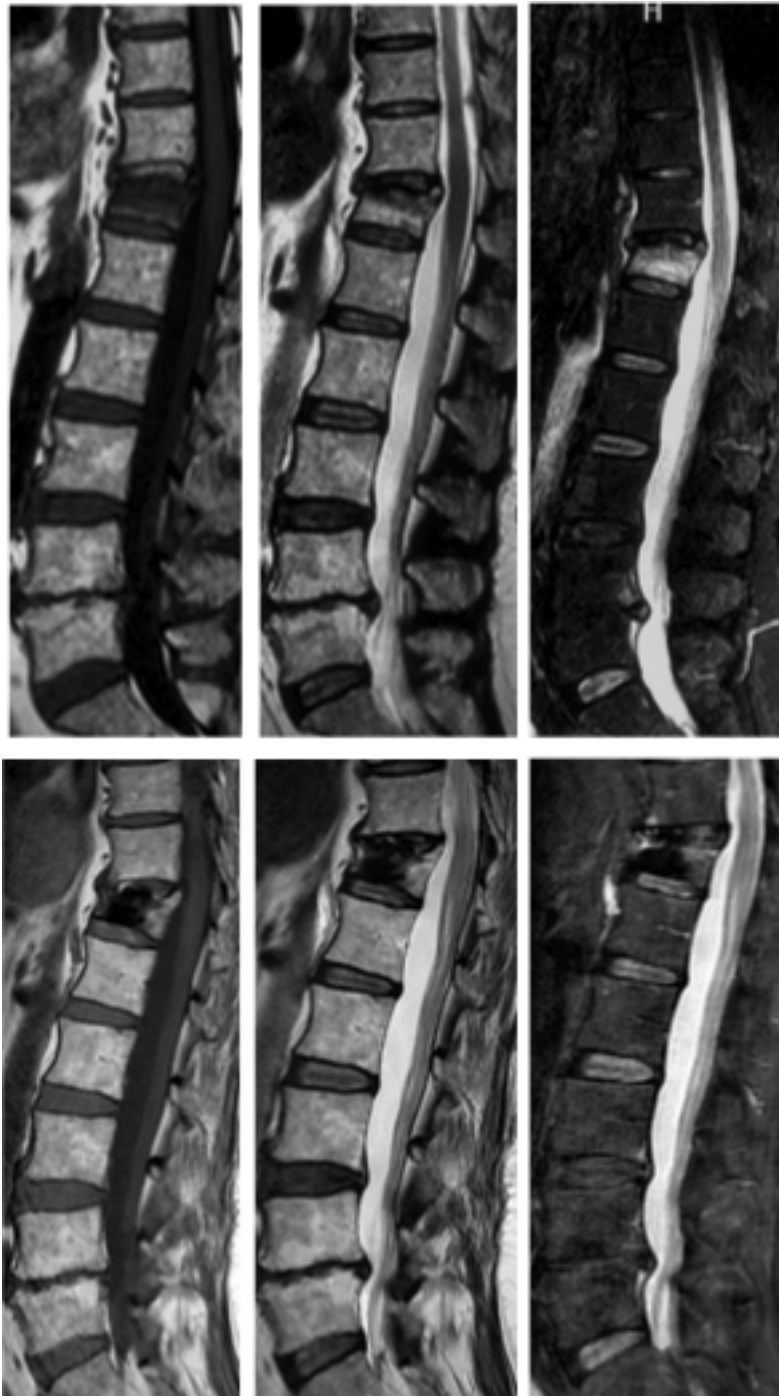**Fig. 1:** **a)** vertebral fracture in the lateral view **b)** and in the antero-posterior view **c)** CT-like axial MPR reconstruction performed to check needle correct pathway **d)** manual drilling performed to create the channels for the implant in the closed fashion **e)** Rotational flat-panel angiographic equipment with cone beam-CT capabilities (Philips Integris Allura XperCT)



**Fig. 2:** **a)** Vertelift implants in the open fashion in lateral view **b)** and in the antero-posterior view (XX fashion) **c)** Vertelift implant in the opened fashion once detached from delivery system in lateral view **d)** and A-P view **e)** manual opening and positioning of Vertelift using handles (“amber” prototype) under fluoroscopic guidance **f)** Vertelift implant in the closed fashion **g)** and in the open fashion (asymmetric)



**Fig. 3:** **a)** Vertelift implants encased in bone cement in lateral view **b)** and in the antero-posterior view **c)** Height measurement before implant expansion in mid-sagittal MPR reconstruction **d)** Height measurements (3 point) before implant expansion in mid-coronal MPR reconstruction **e)** Height measurement after implant expansion and PMMA injection in mid-sagittal **f)** Height measurement after implant expansion and PMMA injection in mid-coronal **g)** PMMA injection using pre-filled cannulae with blunt-tip pusher



**Fig. 4)** *First row from left to right: Magnetic Resonance of the spine T1, T2, STIR sequences showing a wedge fracture with bone marrow edema before vertebral augmentation*  
*Second row from left to right: Magnetic Resonance of the spine performed at 1-year (pt #23) T1, T2, STIR sequences showing no more edema after vertebral augmentation, no new fractures and no significant artifact (just a mild signal void) of VerteLift implant*

## References

1. Jensen ME, McGraw JK, Cardella JF, Hirsch JA. Position statement on percutaneous vertebral augmentation: a consensus statement developed by the American Society of Interventional and Therapeutic Neuroradiology, Society of Interventional Radiology, American Association of Neurological Surgeons/Congress of Neurological Surgeons, and American Society of Spine Radiology. *J Vasc Interv Radiol* 2007;**18**(3):325-30.
2. Galibert P, Deramond H, Rosat P, Le Gars D. [Preliminary note on the treatment of vertebral angioma by percutaneous acrylic vertebroplasty]. *Neurochirurgie* 1987;**33**(2):166-8.
3. Debussche-Depriester C DH, Fardellone P, Heleg A, Sebert JL, Cartz C et al. Percutaneous vertebroplasty with acrylic cement in the treatment of osteoporotic vertebral crush fracture syndrome. *Neuroradiology* 1991;**33** (Suppl):S149-S152.
4. Weill A, Chiras J, Simon JM, Rose M, Sola-Martinez T, Enkaoua E. Spinal metastases: indications for and results of percutaneous injection of acrylic surgical cement. *Radiology* 1996;**199**(1):241-7.
5. Cotten A, Dewatre F, Cortet B, et al. Percutaneous vertebroplasty for osteolytic metastases and myeloma: effects of the percentage of lesion filling and the leakage of methyl methacrylate at clinical follow-up. *Radiology* 1996;**200**(2):525-30.
6. Murphy KJ, Deramond H. Percutaneous vertebroplasty in benign and malignant disease. *Neuroimaging Clin N Am* 2000;**10**(3):535-45.
7. Cardon T, Hachulla E, Flipo RM, et al. Percutaneous vertebroplasty with acrylic cement in the treatment of a Langerhans cell vertebral histiocytosis. *Clin Rheumatol* 1994;**13**(3):518-21.
8. Rami PM, McGraw JK, Heatwole EV, Boorstein JM. Percutaneous vertebroplasty in the treatment of vertebral body compression fracture secondary to osteogenesis imperfecta. *Skeletal Radiol* 2002;**31**(3):162-5.
9. Wilson DR, Myers ER, Mathis JM, et al. Effect of augmentation on the mechanics of vertebral wedge fractures. *Spine (Phila Pa 1976)* 2000;**25**(2):158-65.
10. Lieberman IH, Dudeney S, Reinhardt MK, Bell G. Initial outcome and efficacy of "kyphoplasty" in the treatment of painful osteoporotic vertebral compression fractures. *Spine (Phila Pa 1976)* 2001;**26**(14):1631-8.
11. ACR-ASNR-ASSR-SIR-SNIS. Practice guideline for the performance of vertebroplasty. [www.acr.org](http://www.acr.org) 2009.
12. McGraw JK, Cardella J, Barr JD, et al. Society of Interventional Radiology quality improvement guidelines for percutaneous vertebroplasty. *J Vasc Interv Radiol* 2003;**14**(9 Pt 2):S311-5.
13. Moreland DB, Landi MK, Grand W. Vertebroplasty: techniques to avoid complications. *Spine J* 2001;**1**(1):66-71.
14. Peh WC, Gilula LA, Peck DD. Percutaneous vertebroplasty for severe osteoporotic vertebral body compression fractures. *Radiology* 2002;**223**(1):121-6.



15. O'Brien JP, Sims JT, Evans AJ. Vertebroplasty in patients with severe vertebral compression fractures: a technical report. *AJNR Am J Neuroradiol* 2000;**21**(8):1555-8.
16. Peh WC, Gilula LA, Zeller D. Percutaneous vertebroplasty: a new technique for treatment of painful compression fractures. *Mo Med* 2001;**98**(3):97-102.
17. Gaughen JR, Jr., Jensen ME, Schweickert PA, Kaufmann TJ, Marx WF, Kallmes DF. Lack of preoperative spinous process tenderness does not affect clinical success of percutaneous vertebroplasty. *J Vasc Interv Radiol* 2002;**13**(11):1135-8.
18. Davidson M, Keating JL. A comparison of five low back disability questionnaires: reliability and responsiveness. *Phys Ther* 2002;**82**(1):8-24.
19. Scott J, Huskisson EC. Vertical or horizontal visual analogue scales. *Ann Rheum Dis* 1979;**38**(6):560.
20. Mathis JM, Barr JD, Belkoff SM, Barr MS, Jensen ME, Deramond H. Percutaneous vertebroplasty: a developing standard of care for vertebral compression fractures. *AJNR Am J Neuroradiol* 2001;**22**(2):373-81.
21. Tanigawa N, Komemushi A, Kariya S, et al. Percutaneous vertebroplasty: relationship between vertebral body bone marrow edema pattern on MR images and initial clinical response. *Radiology* 2006;**239**(1):195-200.
22. Maynard AS, Jensen ME, Schweickert PA, Marx WF, Short JG, Kallmes DF. Value of bone scan imaging in predicting pain relief from percutaneous vertebroplasty in osteoporotic vertebral fractures. *AJNR Am J Neuroradiol* 2000;**21**(10):1807-12.
23. Kallmes DF, Jensen ME. Percutaneous vertebroplasty. *Radiology* 2003;**229**(1):27-36.
24. Jensen ME, Evans AJ, Mathis JM, Kallmes DF, Cloft HJ, Dion JE. Percutaneous polymethylmethacrylate vertebroplasty in the treatment of osteoporotic vertebral body compression fractures: technical aspects. *AJNR Am J Neuroradiol* 1997;**18**(10):1897-904.
25. Cotten A, Boutry N, Cortet B, et al. Percutaneous vertebroplasty: state of the art. *Radiographics* 1998;**18**(2):311-20; discussion 320-3.
26. Deramond H, Depriester C, Toussaint P, Galibert P. Percutaneous Vertebroplasty. *Semin Musculoskelet Radiol* 1997;**1**(2):285-296.
27. Cortet B, Cotten A, Boutry N, et al. Percutaneous vertebroplasty in the treatment of osteoporotic vertebral compression fractures: an open prospective study. *J Rheumatol* 1999;**26**(10):2222-8.
28. Jensen ME, Dion JE. Percutaneous vertebroplasty in the treatment of osteoporotic compression fractures. *Neuroimaging Clin N Am* 2000;**10**(3):547-68.
29. Klazen CA, Lohle PN, de Vries J, et al. Vertebroplasty versus conservative treatment in acute osteoporotic vertebral compression fractures (Vertos II): an open-label randomised trial. *Lancet*; **376**(9746):1085-92.
30. Kaufmann TJ, Jensen ME, Schweickert PA, Marx WF, Kallmes DF. Age of fracture and clinical outcomes of percutaneous vertebroplasty. *AJNR Am J Neuroradiol* 2001;**22**(10):1860-3.
31. Brown DB, Gilula LA, Sehgal M, Shimony JS. Treatment of chronic symptomatic vertebral compression fractures with percutaneous vertebroplasty. *AJR Am J Roentgenol* 2004;**182**(2):319-22.
32. Belkoff SM, Mathis JM, Fenton DC, Scribner RM, Reiley ME, Talmadge K. An ex vivo biomechanical evaluation of an inflatable bone tamp used in the treatment of compression fracture. *Spine (Phila Pa 1976)* 2001;**26**(2):151-6.

33. Mathis JM, Ortiz AO, Zoarski GH. Vertebroplasty versus kyphoplasty: a comparison and contrast. *AJNR Am J Neuroradiol* 2004;**25**(5):840-5.
34. Hulme PA, Krebs J, Ferguson SJ, Berlemann U. Vertebroplasty and kyphoplasty: a systematic review of 69 clinical studies. *Spine (Phila Pa 1976)* 2006;**31**(17):1983-2001.
35. Bostrom MP, Lane JM. Future directions. Augmentation of osteoporotic vertebral bodies. *Spine (Phila Pa 1976)* 1997;**22**(24 Suppl):38S-42S.
36. Dahl OE, Garvik LJ, Lyberg T. Toxic effects of methylmethacrylate monomer on leukocytes and endothelial cells in vitro. *Acta Orthop Scand* 1994;**65**(2):147-53.
37. Seppalainen AM, Rajaniemi R. Local neurotoxicity of methyl methacrylate among dental technicians. *Am J Ind Med* 1984;**5**(6):471-7.
38. Nakano M, Hirano N, Ishihara H, Kawaguchi Y, Watanabe H, Matsuura K. Calcium phosphate cement-based vertebroplasty compared with conservative treatment for osteoporotic compression fractures: a matched case-control study. *J Neurosurg Spine* 2006;**4**(2):110-7.
39. Deramond H, Wright NT, Belkoff SM. Temperature elevation caused by bone cement polymerization during vertebroplasty. *Bone* 1999;**25**(2 Suppl):17S-21S.
40. Togawa D, Bauer TW, Lieberman IH, Takikawa S. Histologic evaluation of human vertebral bodies after vertebral augmentation with polymethyl methacrylate. *Spine (Phila Pa 1976)* 2003;**28**(14):1521-7.
41. Eriksson RA, Albrektsson T, Magnusson B. Assessment of bone viability after heat trauma. A histological, histochemical and vital microscopic study in the rabbit. *Scand J Plast Reconstr Surg* 1984;**18**(3):261-8.
42. De Vrind HH, Wondergem J, Haveman J. Hyperthermia-induced damage to rat sciatic nerve assessed in vivo with functional methods and with electrophysiology. *J Neurosci Methods* 1992;**45**(3):165-74.
43. Belkoff SM, Molloy S. Temperature measurement during polymerization of polymethylmethacrylate cement used for vertebroplasty. *Spine (Phila Pa 1976)* 2003;**28**(14):1555-9.
44. Verlaan JJ, Oner FC, Verbout AJ, Dhert WJ. Temperature elevation after vertebroplasty with polymethyl-methacrylate in the goat spine. *J Biomed Mater Res B Appl Biomater* 2003;**67**(1):581-5.
45. Anselmetti GC, Manca A, Kanika K, et al. Temperature measurement during polymerization of bone cement in percutaneous vertebroplasty: an in vivo study in humans. *Cardiovasc Intervent Radiol* 2009;**32**(3):491-8.
46. Heini PF, Berlemann U. Bone substitutes in vertebroplasty. *Eur Spine J* 2001;**10** Suppl 2:S205-13.
47. Middleton ET, Rajaraman CJ, O'Brien DP, Doherty SM, Taylor AD. The safety and efficacy of vertebroplasty using Cortoss cement in a newly established vertebroplasty service. *Br J Neurosurg* 2008;**22**(2):252-6.
48. Palussiere J, Berge J, Gangi A, et al. Clinical results of an open prospective study of a bis-GMA composite in percutaneous vertebral augmentation. *Eur Spine J* 2005;**14**(10):982-91.
49. San Millan Ruiz D, Burkhardt K, Jean B, et al. Pathology findings with acrylic implants. *Bone* 1999;**25**(2 Suppl):85S-90S.
50. Urrutia J, Bono CM, Mery P, Rojas C. Early histologic changes following polymethylmethacrylate injection (vertebroplasty) in rabbit lumbar vertebrae. *Spine (Phila Pa 1976)* 2008;**33**(8):877-82.

51. Antonacci MD, Mody DR, Heggeness MH. Innervation of the human vertebral body: a histologic study. *J Spinal Disord* 1998;**11**(6):526-31.
52. Frasc C, Kravetz P, Mody DR, Heggeness MH. Substance P-containing nerves within the human vertebral body. an immunohistochemical study of the basivertebral nerve. *Spine J* 2003;**3**(1):63-7.
53. McKiernan F, Faciszewski T. Intravertebral clefts in osteoporotic vertebral compression fractures. *Arthritis Rheum* 2003;**48**(5):1414-9.
54. Antonacci MD, Mody DR, Rutz K, Weilbaecher D, Heggeness MH. A histologic study of fractured human vertebral bodies. *J Spinal Disord Tech* 2002;**15**(2):118-26.
55. Belkoff SM, Mathis JM, Jasper LE, Deramond H. The biomechanics of vertebroplasty. The effect of cement volume on mechanical behavior. *Spine (Phila Pa 1976)* 2001;**26**(14):1537-41.
56. Peh WC, Gilula LA. Percutaneous vertebroplasty: indications, contraindications, and technique. *Br J Radiol* 2003;**76**(901):69-75.
57. Gangi A, Kastler BA, Dietemann JL. Percutaneous vertebroplasty guided by a combination of CT and fluoroscopy. *AJNR Am J Neuroradiol* 1994;**15**(1):83-6.
58. Pedicelli A, Rollo M, Piano M, et al. Percutaneous vertebroplasty with a high-quality rotational angiographic unit. *Eur J Radiol* 2009;**69**(2):289-95.
59. Kim AK, Jensen ME, Dion JE, Schweickert PA, Kaufmann TJ, Kallmes DF. Unilateral transpedicular percutaneous vertebroplasty: initial experience. *Radiology* 2002;**222**(3):737-41.
60. Tohmeh AG, Mathis JM, Fenton DC, Levine AM, Belkoff SM. Biomechanical efficacy of unipedicular versus bipedicular vertebroplasty for the management of osteoporotic compression fractures. *Spine (Phila Pa 1976)* 1999;**24**(17):1772-6.
61. Liebschner MA, Rosenberg WS, Keaveny TM. Effects of bone cement volume and distribution on vertebral stiffness after vertebroplasty. *Spine (Phila Pa 1976)* 2001;**26**(14):1547-54.
62. Barr JD, Barr MS, Lemley TJ, McCann RM. Percutaneous vertebroplasty for pain relief and spinal stabilization. *Spine (Phila Pa 1976)* 2000;**25**(8):923-8.
63. Evans AJ, Jensen ME, Kip KE, et al. Vertebral compression fractures: pain reduction and improvement in functional mobility after percutaneous polymethylmethacrylate vertebroplasty retrospective report of 245 cases. *Radiology* 2003;**226**(2):366-72.
64. Zoarski GH, Snow P, Olan WJ, et al. Percutaneous vertebroplasty for osteoporotic compression fractures: quantitative prospective evaluation of long-term outcomes. *J Vasc Interv Radiol* 2002;**13**(2 Pt 1):139-48.
65. Trout AT, Gray LA, Kallmes DF. Vertebroplasty in the inpatient population. *AJNR Am J Neuroradiol* 2005;**26**(7):1629-33.
66. Perez-Higueras A, Alvarez L, Rossi RE, Quinones D, Al-Assir I. Percutaneous vertebroplasty: long-term clinical and radiological outcome. *Neuroradiology* 2002;**44**(11):950-4.
67. Voormolen MH, Lohle PN, Lampmann LE, et al. Prospective clinical follow-up after percutaneous vertebroplasty in patients with painful osteoporotic vertebral compression fractures. *J Vasc Interv Radiol* 2006;**17**(8):1313-20.
68. Lindsay R, Silverman SL, Cooper C, et al. Risk of new vertebral fracture in the year following a fracture. *Jama* 2001;**285**(3):320-3.

69. Grados F, Depriester C, Cayrolle G, Hardy N, Deramond H, Fardellone P. Long-term observations of vertebral osteoporotic fractures treated by percutaneous vertebroplasty. *Rheumatology (Oxford)* 2000;**39**(12):1410-4.
70. Uppin AA, Hirsch JA, Centenera LV, Pfiefer BA, Pazianos AG, Choi IS. Occurrence of new vertebral body fracture after percutaneous vertebroplasty in patients with osteoporosis. *Radiology* 2003;**226**(1):119-24.
71. Kim SH, Kang HS, Choi JA, Ahn JM. Risk factors of new compression fractures in adjacent vertebrae after percutaneous vertebroplasty. *Acta Radiol* 2004;**45**(4):440-5.
72. Baroud G, Bohner M. Biomechanical impact of vertebroplasty. Postoperative biomechanics of vertebroplasty. *Joint Bone Spine* 2006;**73**(2):144-50.
73. Voormolen MH, Lohle PN, Juttman JR, van der Graaf Y, Fransen H, Lampmann LE. The risk of new osteoporotic vertebral compression fractures in the year after percutaneous vertebroplasty. *J Vasc Interv Radiol* 2006;**17**(1):71-6.
74. Hierholzer J, Fuchs H, Westphalen K, Baumann C, Slotosch C, Schulz R. Incidence of symptomatic vertebral fractures in patients after percutaneous vertebroplasty. *Cardiovasc Intervent Radiol* 2008;**31**(6):1178-83.
75. McGirt MJ, Parker SL, Wolinsky JP, Witham TF, Bydon A, Gokaslan ZL. Vertebroplasty and kyphoplasty for the treatment of vertebral compression fractures: an evidenced-based review of the literature. *Spine J* 2009;**9**(6):501-8.
76. Krueger A, Bliemel C, Zettl R, Ruchholtz S. Management of pulmonary cement embolism after percutaneous vertebroplasty and kyphoplasty: a systematic review of the literature. *Eur Spine J* 2009;**18**(9):1257-65.
77. Kim YJ, Lee JW, Park KW, et al. Pulmonary cement embolism after percutaneous vertebroplasty in osteoporotic vertebral compression fractures: incidence, characteristics, and risk factors. *Radiology* 2009;**251**(1):250-9.
78. Birkenmaier C, Seitz S, Wegener B, et al. Acute paraplegia after vertebroplasty caused by epidural hemorrhage. A case report. *J Bone Joint Surg Am* 2007;**89**(8):1827-31.
79. Chen YJ, Tan TS, Chen WH, Chen CC, Lee TS. Intradural cement leakage: a devastatingly rare complication of vertebroplasty. *Spine (Phila Pa 1976)* 2006;**31**(12):E379-82.
80. Chen HL, Wong CS, Ho ST, Chang FL, Hsu CH, Wu CT. A lethal pulmonary embolism during percutaneous vertebroplasty. *Anesth Analg* 2002;**95**(4):1060-2, table of contents.
81. Syed MI, Avutu B, Shaikh A, Sparks H, Mohammed MI, Morar K. Vertebral osteomyelitis following vertebroplasty: is acute a potential contraindication and are prophylactic antibiotics mandatory prior to vertebroplasty? *Pain Physician* 2009;**12**(4):E285-90.
82. Schmid KE, Boszczyk BM, Bierschneider M, Zarfl A, Robert B, Jaksche H. Spondylitis following vertebroplasty: a case report. *Eur Spine J* 2005;**14**(9):895-9.
83. Kallmes DF, Comstock BA, Heagerty PJ, et al. A randomized trial of vertebroplasty for osteoporotic spinal fractures. *N Engl J Med* 2009;**361**(6):569-79.
84. Buchbinder R, Osborne RH, Ebeling PR, et al. A randomized trial of vertebroplasty for painful osteoporotic vertebral fractures. *N Engl J Med* 2009;**361**(6):557-68.

85. Hirsch JA. Vertebral Augmentation Procedures in a post RCT world. *20th GRIBOI meeting Turin (Italy) 2010. Interdisciplinary research conference on injectable biomaterials/biomechanics for minimally invasive clinical application* 2010.
86. Pear R. U.S. to Compare Medical Treatments. <http://www.nytimes.com/2009/02/16/health/policy/16health.html>. *The New York Times* 2009.
87. Grady D. Studies Question Using Cement for Spine Injuries. [http://www.nytimes.com/2009/08/06/health/research/06spine.html?\\_r=2&pagewanted=1](http://www.nytimes.com/2009/08/06/health/research/06spine.html?_r=2&pagewanted=1). *The New York Times* 2009.
88. Meli E. Per le vertebre inutile il cemento. [http://archivioistorico.corriere.it/2009/settembre/13/Per\\_vertebre\\_inutile\\_cemento\\_co\\_9\\_090913084.shtml](http://archivioistorico.corriere.it/2009/settembre/13/Per_vertebre_inutile_cemento_co_9_090913084.shtml). *Corriere della Sera* 2009.
89. Unknown. Vertebroplasty Found to be Useless for Osteoporotic Fracture and Disk Pain. <http://www.beforeyoutakethatpill.com/index.php/2009/08/06/vertebroplasty-found-to-be-useless-for-osteoporotic-fracture-and-disk-pain/>. [www.beforeyoutakethatpill.com](http://www.beforeyoutakethatpill.com) 2009.
90. Noridian. Draft LCD for Vertebroplasty, Vertebral Augmentation; Percutaneous (DL24383). [http://www.cms.gov/mcd/viewlcd.asp?lcd\\_id=31065&lcd\\_version=9&show=all](http://www.cms.gov/mcd/viewlcd.asp?lcd_id=31065&lcd_version=9&show=all). 2010.
91. Mark & Associates PC. Have You Had Surgery Using Spinal Cement?. <http://www.youhaverights.com/medical-devices/spinal-cement/>. 2010.
92. AAOS AAOS. Guideline on the Treatment of Symptomatic Osteoporotic Spinal Compression Fractures. <http://www.aaos.org/research/guidelines/SCFguideline.asp> 2010.
93. SIR SoIR. Society of Interventional Radiology Commentary on Vertebroplasty and the August Studies in the *New England Journal of Medicine*. <http://www.sirweb.org/news/pressReleases.shtml> 2009.
94. Schlaich C, Minne HW, Bruckner T, et al. Reduced pulmonary function in patients with spinal osteoporotic fractures. *Osteoporos Int* 1998;**8**(3):261-7.
95. Kado DM, Lui LY, Ensrud KE, Fink HA, Karlamangla AS, Cummings SR. Hyperkyphosis predicts mortality independent of vertebral osteoporosis in older women. *Ann Intern Med* 2009;**150**(10):681-7.
96. Hiwatashi A, Moritani T, Numaguchi Y, Westesson PL. Increase in vertebral body height after vertebroplasty. *AJNR Am J Neuroradiol* 2003;**24**(2):185-9.
97. Teng MM, Wei CJ, Wei LC, et al. Kyphosis correction and height restoration effects of percutaneous vertebroplasty. *AJNR Am J Neuroradiol* 2003;**24**(9):1893-900.
98. McKiernan F, Faciszewski T, Jensen R. Does vertebral height restoration achieved at vertebroplasty matter? *J Vasc Interv Radiol* 2005;**16**(7):973-9.
99. Babayev M, Lachmann E, Nagler W. The controversy surrounding sacral insufficiency fractures: to ambulate or not to ambulate? *Am J Phys Med Rehabil* 2000;**79**(4):404-9.
100. Dittmer DK, Teasell R. Complications of immobilization and bed rest. Part 1: Musculoskeletal and cardiovascular complications. *Can Fam Physician* 1993;**39**:1428-32, 1435-7.
101. Teasell R, Dittmer DK. Complications of immobilization and bed rest. Part 2: Other complications. *Can Fam Physician* 1993;**39**:1440-2, 1445-6.

102. Diamond TH, Bryant C, Browne L, Clark WA. Clinical outcomes after acute osteoporotic vertebral fractures: a 2-year non-randomised trial comparing percutaneous vertebroplasty with conservative therapy. *Med J Aust* 2006;**184**(3):113-7.
103. Wardlaw D, Cummings SR, Van Meirhaeghe J, et al. Efficacy and safety of balloon kyphoplasty compared with non-surgical care for vertebral compression fracture (FREE): a randomised controlled trial. *Lancet* 2009;**373**(9668):1016-24.
104. Klazen CA, Lohle PN, de Vries J, et al. Vertebroplasty versus conservative treatment in acute osteoporotic vertebral compression fractures (Vertos II): an open-label randomised trial. *Lancet* 2010;**376**(9746):1085-92.
105. Lips P, Cooper C, Agnusdei D, et al. Quality of life in patients with vertebral fractures: validation of the Quality of Life Questionnaire of the European Foundation for Osteoporosis (QUALEFFO). Working Party for Quality of Life of the European Foundation for Osteoporosis. *Osteoporos Int* 1999;**10**(2):150-60.
106. Staxx. MAUDE adverse event report. [http://www.accessdata.fda.gov/scripts/cdrh/cfdocs/cfmaude/detail.cfm?mdrfoi\\_id=1241105](http://www.accessdata.fda.gov/scripts/cdrh/cfdocs/cfmaude/detail.cfm?mdrfoi_id=1241105), 2008.
107. Kim YY, Rhyu KW. Recompression of vertebral body after balloon kyphoplasty for osteoporotic vertebral compression fracture. *Eur Spine J*; **19**(11):1907-12.
108. Heo DH, Chin DK, Yoon YS, Kuh SU. Recollapse of previous vertebral compression fracture after percutaneous vertebroplasty. *Osteoporos Int* 2009;**20**(3):473-80.
109. Upasani VV, Robertson C, Lee D, Tomlinson T, Mahar AT. Biomechanical comparison of kyphoplasty versus a titanium mesh implant with cement for stabilization of vertebral compression fractures. *Spine (Phila Pa 1976)*; **35**(19):1783-8.
110. Moon ES, Kim HS, Park JO, et al. The incidence of new vertebral compression fractures in women after kyphoplasty and factors involved. *Yonsei Med J* 2007;**48**(4):645-52.