

Current state of knowledge on Takotsubo syndrome: a position statement from the task force on Takotsubo syndrome of the Heart Failure Association of the European Society of Cardiology

Alexander R. Lyon^{1,2,*}, Eduardo Bossone³, Birke Schneider⁴, Udo Sechtem⁵, Rodolfo Citro⁶, S.Richard Underwood^{1,2}, Mary N. Sheppard⁷, Gemma A. Figtree^{8,9}, Guido Parodi¹⁰, Yoshihiro J. Akashi¹¹, Frank Ruschitzka¹², Gerasimos Filippatos¹³, Alexandre Mebazaa¹⁴, and Elmir Omerovic¹⁵

¹National Heart and Lung Institute, Imperial College, London, UK; ²NIHR Cardiovascular Biomedical Research Unit, Royal Brompton Hospital, London, UK; ³Cardiology Division, 'Cava de Tirreni and Amalfi Coast' Hospital, Heart Department, University of Salerno, Italy; ⁴Medizinische Klinik II, Sana Kliniken Lübeck, Germany; ⁵Department of Cardiology, Robert Bosch Krankenhaus, Stuttgart, Germany; ⁶University Hospital 'San Giovanni di Dio e Ruggi d'Aragona', Heart Department, Largo Città di Ippocrate, Salerno, Italy; ⁷Department of Cardiovascular Pathology, St George's University Medical School, London, UK; ⁸North Shore Heart Research, Kolling Institute, University of Sydney, Australia; ⁹Department of Cardiology, Royal North Shore Hospital, Sydney, Australia; ¹⁰Invasive Cardiology, Careggi Hospital, Florence, Italy; ¹¹Division of Cardiology, Department of Internal Medicine, St. Marianna University School of Medicine, Kawasaki, Japan; ¹²Clinic for Cardiology, University Hospital Zurich, Zurich, Switzerland; ¹³Department of Cardiology, Attikon University Hospital, University of Athens Medical School, Athens, Greece; ¹⁴Université Paris Diderot; U942 Inserm, Département d'Anesthésie-Réanimation Hôpitaux Universitaires Saint Louis-Lariboisière, Paris, France; and ¹⁵Department of Molecular and Clinical Medicine/Cardiology, Sahlgrenska Academy, University of Gothenburg, Gothenburg, Sweden

Received 18 December 2014; revised 25 July 2015; accepted 4 August 2015; online publish-ahead-of-print 9 November 2015

Takotsubo syndrome is an acute reversible heart failure syndrome that is increasingly recognized in modern cardiology practice. This Position Statement from the European Society of Cardiology Heart Failure Association provides a comprehensive review of the various clinical and pathophysiological facets of Takotsubo syndrome, including nomenclature, definition, and diagnosis, primary and secondary clinical subtypes, anatomical variants, triggers, epidemiology, pathophysiology, clinical presentation, complications, prognosis, clinical investigations, and treatment approaches. Novel structured approaches to diagnosis, risk stratification, and management are presented, with new algorithms to aid decision-making by practising clinicians. These also cover more complex areas (e.g. uncertain diagnosis and delayed presentation) and the management of complex cases with ongoing symptoms after recovery, recurrent episodes, or spontaneous presentation. The unmet needs and future directions for research in this syndrome are also discussed.

Keywords

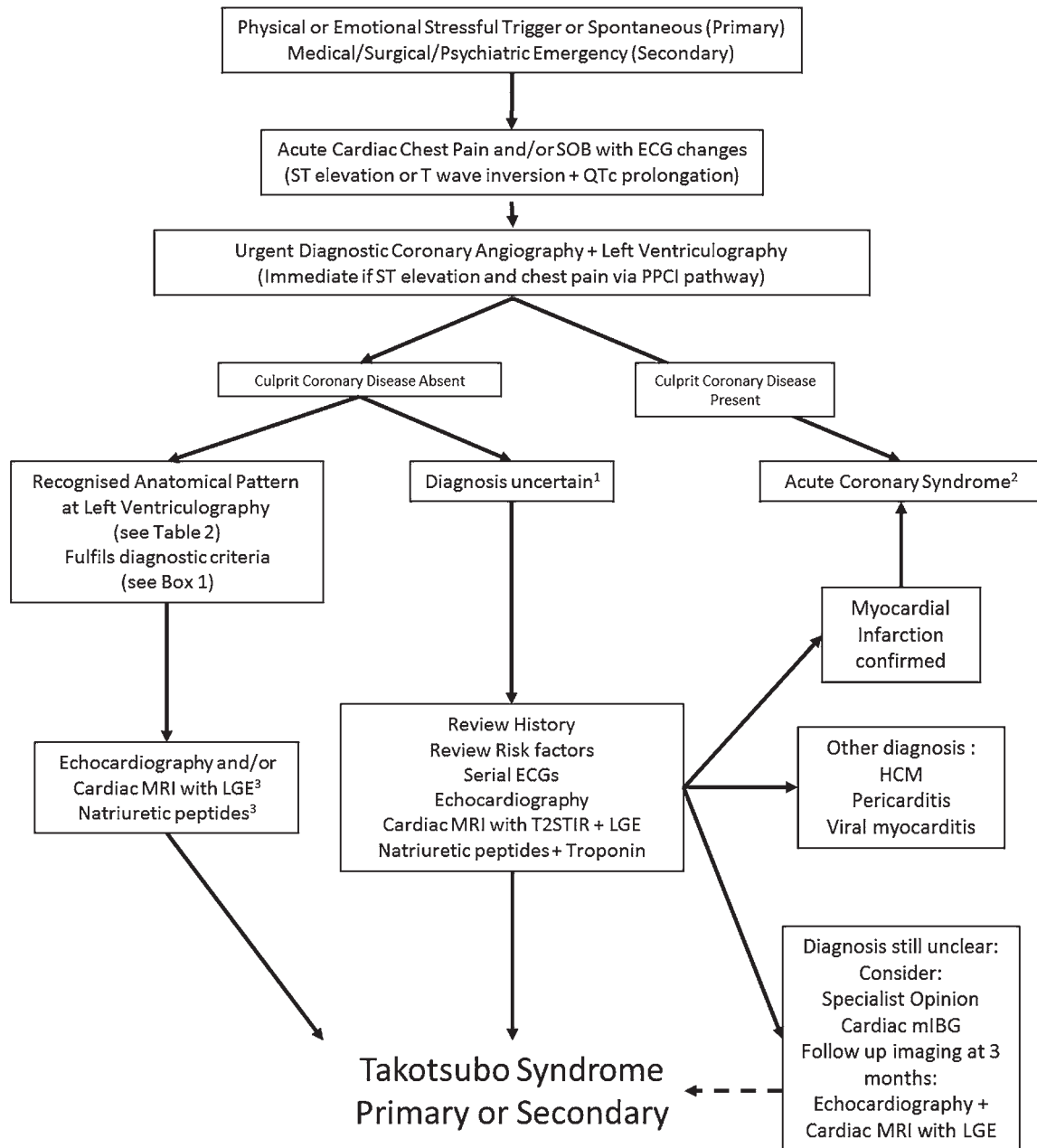
Takotsubo syndrome • stress • heart failure • risk stratification

Executive summary

- **Nomenclature:** 'Takotsubo syndrome' is recommended as the formal name for this condition, and the term cardiomyopathy is avoided.

- **Diagnosis:** a new set of seven diagnostic criteria is proposed incorporating anatomical features, ECG changes, cardiac biomarkers, and reversibility of the myocardial dysfunction (*Box 1; Diagnostic algorithm*).
- **Clinical subtypes:** classification as 'primary' or 'secondary' Takotsubo syndrome, depending on clinical context and presence of

*Corresponding author: NIHR Cardiovascular Biomedical Research Unit, Royal Brompton Hospital, Sydney Street, London SW3 6NP, UK. Tel +44 207 352 8121, Fax +44 207 351 8776, Email: a.lyon@ic.ac.uk

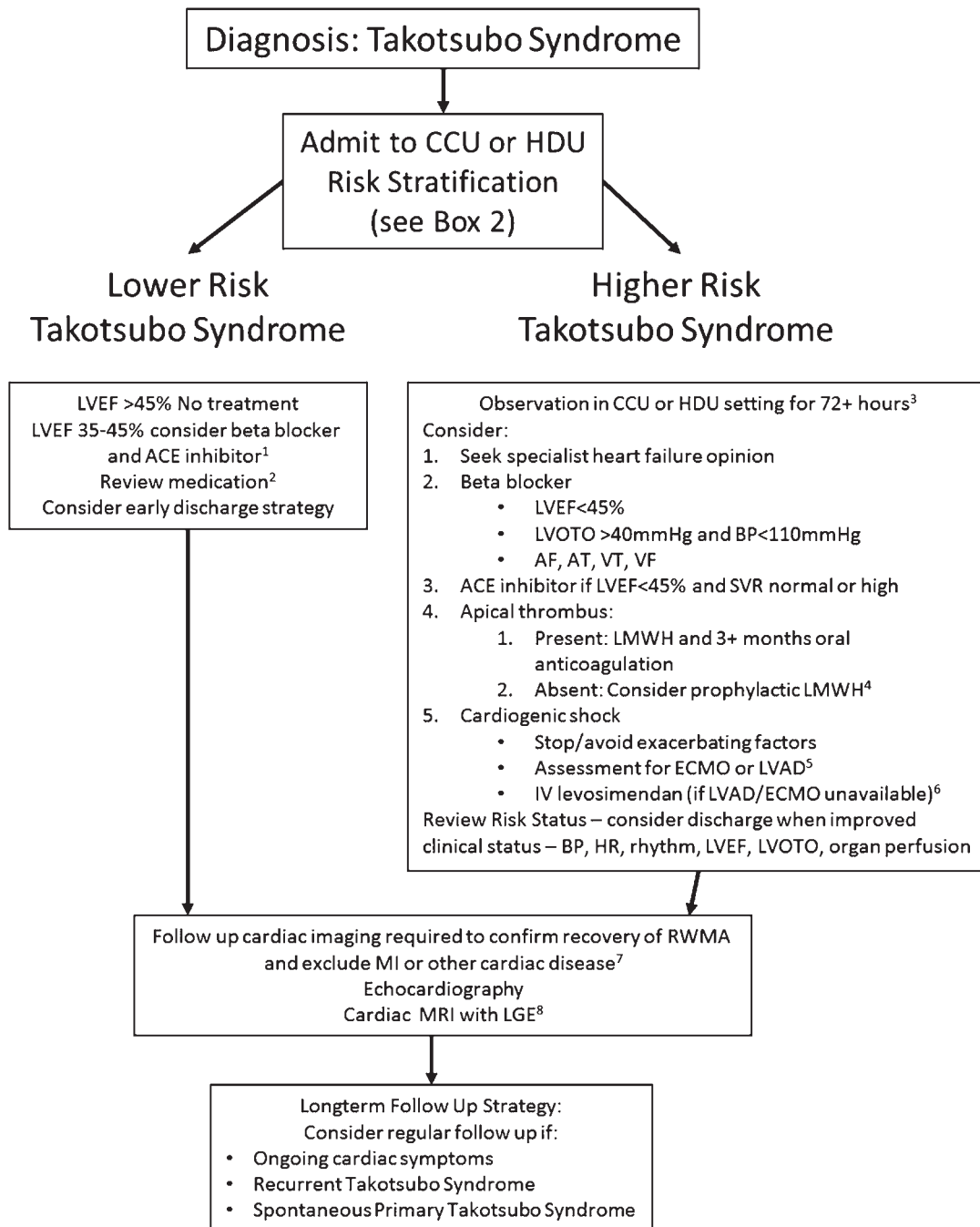


1. For example fulfils some but not all HFA Takotsubo Syndrome diagnostic criteria (significant one vessel coronary artery disease present; late presentation with possible partial or complete LV systolic recovery; atypical risk factor profile).
2. See ESC Guidelines for the management of acute myocardial infarction in patients presenting with ST-segment elevation and ESC Guidelines for the management of acute coronary syndromes in patients presenting without persistent ST-segment elevation.
3. If available.

Takotsubo Syndrome Diagnostic Algorithm

- a major medical, surgical, obstetric, or psychiatric emergency triggering the Takotsubo syndrome episode.
- **Triggers:** a stressful trigger is typical but not always present. Triggers can be emotional or physical, including acute medical, surgical, obstetric, or psychiatric emergencies (Table 1).
- **Anatomical variants:** three common and several rare anatomical variants are currently recognized (Table 2).

- **Epidemiology:** Takotsubo syndrome is increasingly recognized and reported, and many features suggest a different pathophysiological condition from coronary atherosclerosis. Takotsubo syndrome appears to be more common than previously recognized, but the precise incidence is not known.
- **Complications:** cardiac and non-cardiac complications are common during the acute episode (Table 3).



1. Consider carvedilol unless contraindicated.
2. Consider stopping statin and antiplatelet agents if started prior to coronary angiography unless otherwise indicated (e.g. coronary artery disease).
3. Continuous ECG monitoring with defibrillator and resuscitation equipment available.
4. Apical variants with a large apical akinetic zone.
5. Especially in primary Takotsubo syndrome with cardiogenic shock and progressive organ dysfunction.
6. Avoid loading dose, and levosimendan is contraindicated in patients with LVOTO or low SVR.
7. Consider repeat imaging 3-6 months following acute admission unless earlier imaging is indicated for other clinical reasons.
8. If available.

Takotsubo Syndrome Management Algorithm

Box 1 Heart Failure Association diagnostic criteria for Takotsubo syndrome

1. Transient regional wall motion abnormalities of LV or RV myocardium which are frequently, but not always, preceded by a stressful trigger (emotional or physical).
2. The regional wall motion abnormalities usually^a extend beyond a single epicardial vascular distribution, and often result in circumferential dysfunction of the ventricular segments involved.
3. The absence of culprit atherosclerotic coronary artery disease including acute plaque rupture, thrombus formation, and coronary dissection or other pathological conditions to explain the pattern of temporary LV dysfunction observed (e.g. hypertrophic cardiomyopathy, viral myocarditis).
4. New and reversible electrocardiography (ECG) abnormalities (ST-segment elevation, ST depression, LBBB^b, T-wave inversion, and/or QTc prolongation) during the acute phase (3 months).
5. Significantly elevated serum natriuretic peptide (BNP or NT-proBNP) during the acute phase.
6. Positive but relatively small elevation in cardiac troponin measured with a conventional assay (i.e. disparity between the troponin level and the amount of dysfunctional myocardium present).^c
7. Recovery of ventricular systolic function on cardiac imaging at follow-up (3–6 months).^d

^aAcute, reversible dysfunction of a single coronary territory has been reported.

^bLeft bundle branch block may be permanent after Takotsubo syndrome, but should also alert clinicians to exclude other cardiomyopathies. T-wave changes and QTc prolongation may take many weeks to months to normalize after recovery of LV function.

^cTroponin-negative cases have been reported, but are atypical.

^dSmall apical infarcts have been reported. Bystander subendocardial infarcts have been reported, involving a small proportion of the acutely dysfunctional myocardium. These infarcts are insufficient to explain the acute regional wall motion abnormality observed.

- *Risk stratification*: after confirmed or suspected diagnosis of Takotsubo syndrome, risk stratification is recommended to guide treatment (*Management algorithm*; Box 4).
- *Treatment*: a new management algorithm is proposed, based on risk stratification into higher risk and lower risk pathways (*Management algorithm*).
- *Recurrence*: management of recurrent Takotsubo syndrome and the role of prophylactic treatment are discussed. Currently no evidence supports prophylactic treatment after the first presentation.

implies that multiple pathophysiological processes may converge to generate a similar clinical phenotype. As a result, clinical decisions are challenging, and many patients currently receive a 'default' ACS management strategy.

The published literature on Takotsubo syndrome and related stress-induced cardiac syndromes consists of case reports, case series, observational cohorts from screening discharge coding across healthcare networks, and data collected from national Takotsubo syndrome registries. These registries vary in size but are generally considered small by contemporary standards (<600 patients). This current published information is level of evidence C for conventional clinical guidelines. This document is a Position Statement and not a guideline; current evidence was reviewed by a group of experts with a specialist interest in Takotsubo syndrome who provided their opinion and consensus of the current best practice for the diagnosis and management of patients with Takotsubo syndrome.

Introduction

Takotsubo syndrome is an acute and usually reversible heart failure syndrome first described in 1990 which is increasingly recognized with access to urgent coronary angiography for patients with acute 'cardiac' chest pain.¹ Since the initial description, the clinical community has increasingly recognized that this syndrome is distinct from acute coronary syndrome (ACS), although the initial presentation has similar features to ST-segment elevation myocardial infarction (STEMI) or non-ST-segment elevation myocardial infarction (NSTEMI).^{2–10} Early access to diagnostic coronary angiography has helped identify this condition, and the number of case reports, series, and registries reported has increased over the last 25 years, offering different insights into this syndrome.¹¹

To date there have been no randomized trials to define the optimal management of patients with suspected Takotsubo syndrome, with respect to both diagnosis and treatment. The increasing variety of clinical contexts in which this syndrome has been described

Nomenclature

Various names have been used to describe the acute appearance now classically described as a 'Takotsubo cardiomyopathy' or 'Takotsubo syndrome', following the initial label given by Sato and colleagues in 1990 and 1991, which reflects the resemblance of the left ventricle at end-systole to the octopus pots of Japanese fisherman in the Hiroshima fish markets.¹² Many alternatives names have been used, including stress or stress-induced cardiomyopathy,¹³ apical ballooning syndrome,³ ampullary-shaped

Table 1 Triggers for secondary Takotsubo syndrome

Endocrine
e.g. Pheochromocytoma, thyrotoxicosis (endogenous and iatrogenic), SIADH, Addisonian crisis, multiple endocrine neoplasia 2A syndrome, hyperglycaemic hyperosmolar state, hyponatraemia, severe hypothyroidism, Addison's disease, adrenocorticotropin hormone deficiency, autoimmune polyendocrine syndrome II
Neurological and neurosurgical
Acute neurosurgical emergencies (e.g. subarachnoid haemorrhage, acute head injury, acute spinal injury)
Acute neuromuscular crises, especially if involving acute ventilatory failure (e.g. acute myasthenia gravis, acute Guillain–Barré syndrome)
Epileptic seizures, limbic encephalitis, ischaemic stroke, posterior reversible encephalopathy syndrome
Respiratory
Acute exacerbation of asthma or COPD (especially with excessive use of inhaled beta2-agonists)
Acute pulmonary embolism
Acute pneumothorax
Obstetric, e.g. miscarriage, labour, emergency Caesarean section
Psychiatric
Acute anxiety attack/panic disorder
Attempted suicide
Drug-withdrawal syndromes
Electroconvulsive therapy
Gastrointestinal, e.g. acute cholecystitis, biliary colic, acute pancreatitis, severe vomiting, severe diarrhoea, pseudomembranous colitis, peritonitis
Infection
Severe sepsis
Babesiosis
Cardiological
Dobutamine stress echocardiography
Radiofrequency arrhythmia ablation
Pacemaker implantation
Electrical DC cardioversion for atrial fibrillation
Post-cardiac arrest including ventricular fibrillation
Haematological
Blood transfusions
Thrombotic thrombocytopenic purpura
Surgical
Many cases have been reported during induction of general anaesthesia or during non-cardiac surgery or interventional procedures under local or general anaesthesia (e.g. cholecystectomy, hysterectomy, rhinoplasty, Caesarean section, radiofrequency liver ablation, radiotherapy, colonoscopy, difficult urinary catheterization, carotid endarterectomy)
Medication and illicit drugs
Epinephrine injection
Nortriptyline overdose, venlafaxine overdose, albuterol, flecainide, metoprolol withdrawal, 5-fluorouracil, duloxetine
Cocaine abuse

SIADH, syndrome of inappropriate antidiuretic hormone secretion.

cardiomyopathy,^{14,15} and 'broken heart syndrome' in the context of bereavement.¹⁶

The authors suggest 'Takotsubo syndrome' as a unifying term for this clinical entity. 'Takotsubo' has now become engrained in both medical literature and teaching, and several Takotsubo registries have been established.^{17–21} Since the diagnosis is currently based on a series of clinical observations (see below), there is consensus that it fulfils the definition of a clinical syndrome. The term 'cardiomyopathy' implies a primary disease of the cardiac muscle and in clinical cardiology is usually applied to a primary heart muscle disorder of genetic or unknown origin. Patients with Takotsubo syndrome do not appear to have a primary muscle disorder, and no common genetic basis has been

identified. The full recovery of patients and the low rate of major adverse cardiac events at follow-up in reported series strongly suggest that Takotsubo syndrome is different from the primary cardiomyopathies.

Definition

Takotsubo syndrome and associated variants are a form of acute and usually reversible heart failure syndrome. It may be a form of acute catecholaminergic myocardial stunning, as there is no occlusive CAD to explain the pattern of temporary LV dysfunction observed. Patients with Takotsubo syndrome have typical features that must be identified to confirm the diagnosis. Several previous

Table 2 Anatomical variants of Takotsubo syndrome

Variant	Estimated prevalence
Apical with or without MLV variant (typical)	75–80%
MLV	~10–15%
Inverted or basal	~5%
Biventricular	Clinical <0.5%; CMR 33%
Right ventricular	Unknown
Apical tip sparing	Unknown
Possible atypical variants	
Global	Unknown
Focal	Unknown

CMR, cardiac magnetic resonance; MLV, mid-left ventricular;

Table 3 In-hospital and long-term outcome of Takotsubo syndrome

Complication/outcome	Frequency
Acute complications	
Right ventricular involvement	18–34%
Acute heart failure	12–45%
LV outflow tract obstruction	10–25%
Mitral regurgitation	14–25%
Cardiogenic shock	6–20%
Arrhythmias	
Atrial fibrillation	5–15%
Ventricular arrhythmias	4–9%
Bradycardia, asystole	2–5%
Thrombus formation	2–8%
Pericardial tamponade	<1%
Ventricular wall rupture	<1%
In-hospital mortality	1–4.5%
Recurrence	5–22%
5-year mortality	3–17%

diagnostic criteria have been proposed, including those by the Mayo Clinic (modified in 2008), the Japanese Takotsubo Cardiomyopathy Group, the Gothenburg Group, and the Takotsubo Italian Network.^{4,20,22–24}

We have reviewed, adapted, and amended these criteria to generate the new 2015 Heart Failure Association of the European Society of Cardiology (HFA) Takotsubo Syndrome Diagnostic Criteria (Box 1). Although this condition predominantly affects post-menopausal women (~90% of all cases reported, particularly in larger cohorts), men and younger women can have this condition. Therefore, these demographic features are not a mandatory part of the proposed diagnostic criteria. Takotsubo syndrome is reversible—a critical feature that helps to differentiate it from many other acute heart failure syndromes. Timelines of recovery vary depending on the severity of the acute episode. As a guide, LVEF usually recovers by 12 weeks, but ECG changes and BNP levels may take 6–12 months to recover and, in some cases, can remain permanently abnormal, e.g. if myocardial scarring occurs.

Distinguishing Takotsubo syndrome from acute infective myocarditis can be challenging if there is evidence of acute myocardial oedema and inflammation in a typical anatomical distribution, as is common during the acute episode of Takotsubo syndrome (Box 2).^{25–27} This could be considered a form of acute catecholaminergic myocarditis, given the appearance on T2-STIR cardiac magnetic resonance (CMR) and the rise in cardiac troponin. A careful history and other clinical features can normally differentiate these conditions (e.g. the stressful trigger, if present, in Takotsubo syndrome vs. the viral prodromal illness with fever in acute infective myocarditis).²⁸

Another difference from the modified Mayo diagnostic criteria is the inclusion of pheochromocytoma. In patients with this condition, and particularly those with an epinephrine-secreting pheochromocytoma, acute Takotsubo syndrome may result from a catecholamine storm, in an analogous manner to a catecholamine storm after a sudden stressful experience.^{29–34} The pathophysiology and clinical phenotype are identical, and therefore the consensus of the authors was to include patients with pheochromocytoma but to consider them as cases of secondary Takotsubo syndrome (Table 1).

Clinical subtypes: primary and secondary Takotsubo syndrome

Takotsubo syndrome comes to the attention of medical personnel in a variety of clinical scenarios and contexts. Cases can be classified as either primary or secondary Takotsubo syndrome.

Primary Takotsubo syndrome

In primary Takotsubo syndrome, the acute cardiac symptoms are the primary reason for seeking care, usually from emergency medical services, acute cardiac services, or the primary care physician. Such patients may or may not have clearly identifiable stressful triggers (often emotional). Potential co-existing medical conditions may be the predisposing risk factors but are not the primary cause of the catecholamine rise. These cases can be considered primary Takotsubo syndrome, and their clinical management depends on the specific complications.

Secondary Takotsubo syndrome

A substantial proportion of cases occur in patients already hospitalized for another medical, surgical, anaesthetic, obstetric, or psychiatric condition. In these patients, sudden activation of the sympathetic nervous system or a rise in catecholamines precipitates an acute Takotsubo syndrome as a complication of the primary condition or its treatment. We propose that such cases be diagnosed as secondary Takotsubo syndrome. Their management should focus not only on the Takotsubo syndrome and its cardiac complications but also on the condition that triggered the syndrome. Examples of medical conditions reported to trigger secondary Takotsubo syndrome are listed in Table 1.

Box 2 Differences between Takotsubo syndrome and acute myocarditis

Category	Takotsubo syndrome	Acute myocarditis
Gender and age	90% female. Majority >50 years and post-menopausal.	No sex prevalence. More frequent in the young.
Preceding events	Stressor trigger identifiable in ~70% of cases.	Symptoms and signs of infection often present (fever, chills, headache, muscle aches, general malaise, cough, nausea, vomiting, diarrhoea).
Cardiac symptoms	Chest pain, dyspnoea, palpitations.	Chest pain, dyspnoea, peripheral oedema, fatigue, and palpitations.
Clinical signs	Pericardial rub rare.	Pericardial rub may be present.
ECG at admission	ST changes such as ST-segment elevation or non ST-segment elevation. Deep T wave inversion. QT prolongation. Rarely normal.	ST-segment elevation or depression, negative T-wave, bundle branch block, atrioventricular block, low voltage, and/or ventricular arrhythmias. Normal in several cases.
Cardiac enzymes	Low/moderate troponin rise. Discrepancy between the large amount of dysfunctional myocardium and peak troponin level.	Frequently significant troponin rise, proportional to the hypokinetic area. Normal in several cases.
Other biomarkers	C-reactive protein (CRP) mildly elevated unless infective trigger. BNP moderately or significantly elevated.	Erythrocyte sedimentation rate and CRP elevated. BNP basically elevated. Acute viral serology may be detected.
Echocardiography	Apical ballooning, anatomical variants, 'circumferential pattern', left ventricular outflow tract obstruction (LVOTO), right ventricular (RV) involvement, transient mitral regurgitation.	Localized or diffuse wall motion abnormalities of LV and/or RV dilatation, increased wall thickness, pericardial effusion.
Cardiac magnetic resonance imaging	High T2 signal intensity (oedema), late gadolinium enhancement (LGE) usually absent acutely. If present acutely patchy LGE which usually resolves at follow-up. Absence of typical infarct LGE pattern.	High T2 signal intensity (oedema), LGE with non-ischaemic distribution (often epicardial). Absence of typical infarct LGE pattern.
Histological findings	Contraction band necrosis.	Infiltration of many inflammatory cells. Interstitial oedema.
Viral genome, separation of virus, or identification of virus by antibody titre	Rare and usually absent where measured.	Often positive.
Prognosis	50% of cases have acute complications, 4–5% mortality.	Variable but majority full recovery. Highest mortality with fulminant myocarditis.
Therapy	Supportive.	Supportive. Immunosuppression in severe cases if giant cell myocarditis suspected.

Anatomical variants

Primary and secondary Takotsubo syndromes encompass an array of anatomical variants (Table 2; Figure 1).^{35–37} The initial report of Takotsubo syndrome described what is now considered the classical pattern: LV regional wall motion abnormality (RWMA) with apical and circumferential mid-ventricular hypokinesia and basal hypercontractility. At end-systole, the left ventricle typically resembles the 'Takotsubo' with a narrow neck and globular lower portion, giving the appearance of virtual apical ballooning. This

typical variant with apical dysfunction is present in ~50–80% cases, depending on the series.

Two other variants are common: the inverted Takotsubo or basal variant, with circumferential basal hypokinesia and apical hypercontractility, also referred to as the 'nutmeg' or 'artichoke' heart; and the mid left ventricular (MLV) variant, with circumferential mid-ventricular hypokinesia and both basal and apical hypercontractility.^{38–40} The end-systolic appearance of the MLV variant has been likened to a Greek vase or the ace of spades; however, the basal variant can also resemble the ace of spades (Figure 1).

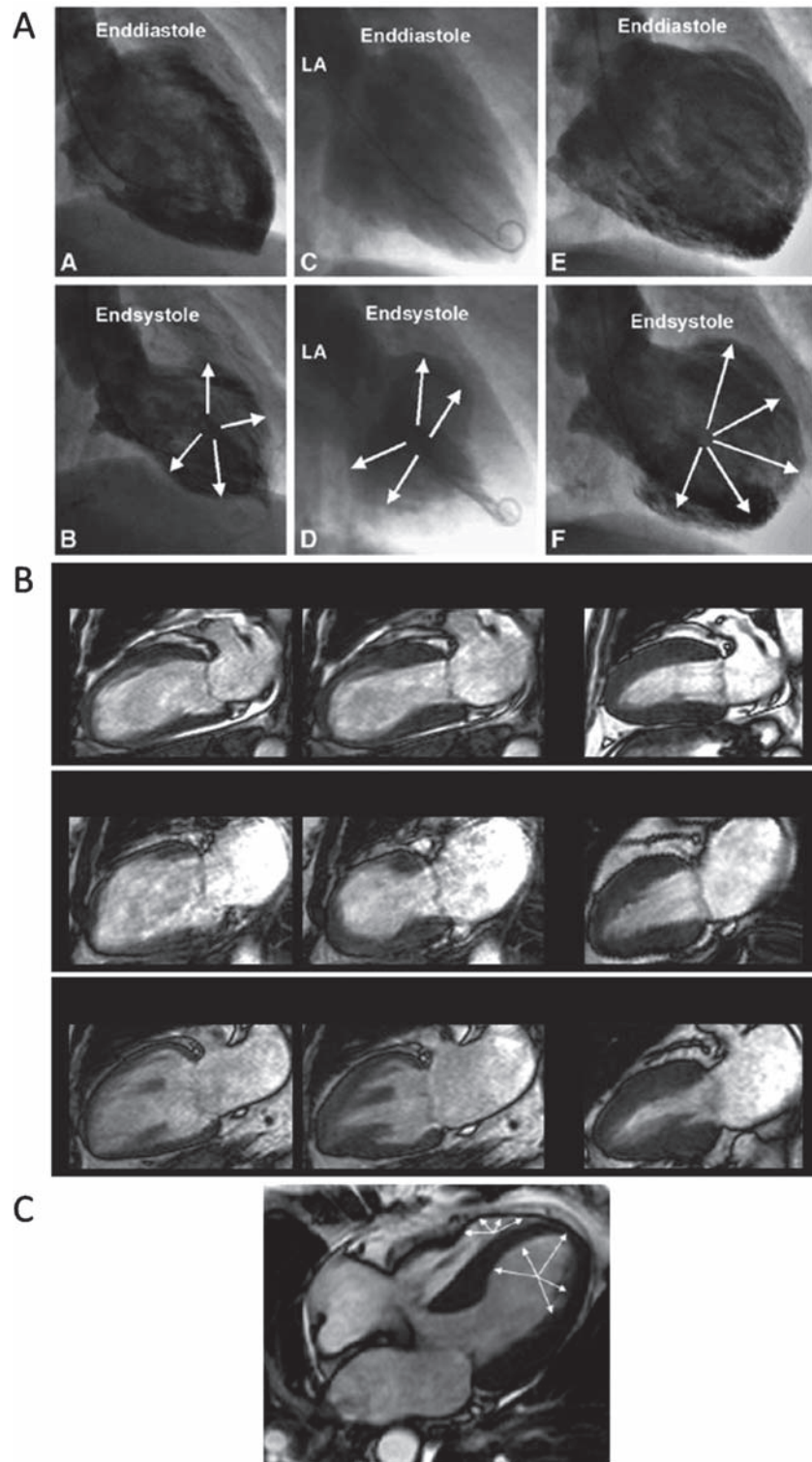


Figure 1 Anatomical variants of Takotsubo syndrome. (A) Ventriculographic appearances showing paired end-diastolic image (above) and end-systolic image (below) of a mid-ventricular variant (A and B), an inverted Takotsubo variant (C and D), and a typical apical Takotsubo variant (E and F). Adapted from Haghi *et al.*¹³⁸ (B) Cardiac magnetic resonance (CMR) appearances showing paired acute end-diastolic (left), acute end-systolic (centre), and follow-up end-systolic (right) images for typical apical Takotsubo syndrome (top row), mid-ventricular variant (middle row), and inverted Takotsubo variant (lower row) (reproduced from Eitel *et al.*³⁵). (C) Biventricular involvement with LV and RV apical hypokinesia. White arrows highlight regions of hypokinesia in the end-systolic four-chamber view (adapted from Haghi *et al.*³⁶).

In both of these variants, reversible LV dysfunction affects more than one coronary territory, usually in a circumferential pattern, in the absence of culprit CAD. Rarer variants include biventricular apical dysfunction, dysfunction sparing the apical tip (possibly a form of MLV Takotsubo), and isolated right ventricular (RV) Takotsubo syndrome.^{36,41–43}

The affected LV segments may recover at different rates, a possible explanation for the various anatomical variants observed. Intriguingly, Takotsubo syndrome may recur as a different anatomical variant in the same patient, suggesting that a person can be susceptible to more than one subtype.^{44,45}

Epidemiology

Several series of Asian and Western (predominantly Caucasian) populations suggest that 1–2% of patients with suspected ACS are eventually diagnosed with Takotsubo syndrome.^{7,37} In those series, the incidence of Takotsubo syndrome was probably underestimated. The possibility of pre-hospital sudden cardiac death from Takotsubo syndrome was not considered and, with increasing awareness and more widespread access to early coronary angiography, Takotsubo syndrome is now recognized more frequently.

The largest reported cohorts are from the Nationwide Inpatient Sample (NIS-USA). However, these reports were based on ICD-10 (International Disease Classification 10th Revision) discharge coding, with no uniform system for ensuring correct diagnosis or estimating the number of cases missed. This registry represents ~20% of all US non-federal community hospitals. The first NIS-USA study reported data on 6837 patients with Takotsubo syndrome from 2008.⁴⁶ The second NIS-USA study reported data from 24 701 patients from 2008–2009; it appears to be a 24-month data set, but may include patients in the first study.⁴⁷ These numbers imply that there are ~50 000–100 000 cases per annum in the USA, with similar estimated numbers in Europe.

In the first study, Takotsubo syndrome was diagnosed in 0.02% of all acute hospitalizations (6837/33 506 402 patients).⁴⁶ The majority (90%) were elderly post-menopausal women (66–80 years of age), a demographic repeated across many published cohorts. The risk factors included smoking, alcohol abuse, anxiety states, and hyperlipidaemia. The second study, and largest cohort to date, reported details of 24 701 patients with a discharge code for Takotsubo syndrome. The demographics were similar to those in the first study: 89% were women, the mean age was 66.9 ± 30.7 years, and most patients (59.6%) were ≥ 65 years old.⁴⁷

Gender differences

Takotsubo syndrome occurs predominantly in post-menopausal women. The German Takotsubo syndrome registry includes 324 patients; 91% are female (mean age 68 ± 12 years) and 9% are male (mean age 66 ± 12 years). The demographic and clinical characteristics were similar in men and women.¹⁷ However, emotional stress or the absence of identifiable triggers was more common in women. Conversely, a physical stressful triggering event, shock, or resuscitation on presentation was more common in men, who also had higher levels of cardiac biomarkers (troponin). In the larger

of the two NIS-USA cohorts, the mortality rate was higher in men (8.4% vs. 3.6%, $P < 0.0001$), perhaps reflecting the higher frequency of underlying severe critical illness and secondary Takotsubo syndrome (36.6% in men vs. 26.8% in women, $P < 0.0001$).⁴⁷

Age

Elderly patients are considered to be at higher risk of Takotsubo syndrome and related major complications, and <10% of patients are below 50 years of age.^{46,48} In the Takotsubo Italian Network, Takotsubo syndrome patients older than 65 years have a greater prevalence of hypertension and cerebrovascular disease, a lower glomerular filtration rate, and a lower LVEF at discharge compared with younger patients. Older adults (≥ 75 years) have higher rates of in-hospital complications and in-hospital mortality (6.3% vs. 2.8% overall in-hospital mortality).¹⁸

Pathophysiology

The pathophysiology of Takotsubo syndrome is complex and reflects the integrated and systemic physiological responses to acute, severe stress and the cardiovascular responses to sudden surges in endogenous or exogenously administered catecholamines. The pathophysiology has been extensively reviewed elsewhere.^{10,49–52}

Catecholamines appear to have a central role in the pathophysiology of Takotsubo syndrome, as the trigger is often a sudden, unexpected stress; signs of sympathetic activation are present at presentation, and secondary medical triggers can also lead to extreme sympathetic activation. There are two initial elements of the physiology to consider. The first is the cognitive centres of the brain and hypothalamic–pituitary–adrenal (HPA) axis, and how much epinephrine and norepinephrine are released in response to a given stress (i.e. the ‘gain’ of the HPA axis). The second is the response of the cardiovascular system (including the myocardium, coronary arteries, and peripheral vasculature) and the sympathetic nervous system to the sudden sympathetic activation and surge in circulating catecholamines.

Serum catecholamine levels at presentation are significantly higher than resting levels in the same patient or in comparable patients with acute heart failure due to acute myocardial infarction (MI), suggesting the potential for excessive HPA gain and epinephrine release.⁵³ Iatrogenic Takotsubo syndrome has been reported after administration of sympathomimetic drugs (e.g. dobutamine in stress echocardiography).⁵⁴

Several hypotheses have been proposed to explain the unique cardiac appearance in Takotsubo syndrome and the cardiac response to severe stress. These hypotheses can be broadly divided into vascular and myocardial causes (Box 3) and may not be mutually exclusive, as the entire cardiovascular system is exposed to the same catecholamine storm. Many of these hypotheses are still being investigated, as there is no current proven pathophysiological mechanism to explain Takotsubo syndrome. There may be a synergistic combination of more than one factor, and mechanistic studies have yielded conflicting results.

Box 3 Summary of pathophysiological hypotheses

Vascular	Acute multivessel coronary spasm. Aborted myocardial infarction with spontaneous recanalization.
Myocardial	Acute increased ventricular afterload. Acute left ventricular outflow tract obstruction. Direct catecholamine-mediated myocardial stunning.
Vascular and myocardial	Integrated cardiovascular physiology (a cardio-circulatory syndrome).

Genetic susceptibility

The stressful trigger implies that the pathophysiology of Takotsubo syndrome has a strong environmental component. However, it is conceivable that some people have a genetic predisposition to stress-induced Takotsubo syndrome. Although the syndrome is not considered a primary genetic cardiomyopathy, a number of studies have explored the possibility of genetic risk factors. A genetic predisposition has been suggested based on the few familial Takotsubo syndrome cases described.^{55–58} Conflicting results have been published regarding the presence or absence of functional polymorphisms in relevant candidate genes, such as $\alpha 1$ -, $\beta 1$ -, and $\beta 2$ -adrenergic receptors, *GRK5*, and oestrogen receptors. These studies had relatively small numbers of subjects. Resolving these conflicts will require high-quality phenotyping, identification of candidate genes, and sharing of high-number/high-quality data in a Takotsubo syndrome network.

Clinical presentation and diagnosis

The typical patient with primary Takotsubo syndrome is a post-menopausal woman who has experienced severe, unexpected emotional or physical stress.⁴ This may be unheralded or on the background of elevated levels of stress or anxiety, including in some cases a formal diagnosis of anxiety or panic disorder.^{46,59} However, most patients do not have prior history of stress-related psychological conditions. Nevertheless, it is important to remember that 10% of cases in the largest reported series (NIS-USA) were men or younger women, and 30–35% of cohort series report classical cases in patients with no identifiable stressful trigger.⁴⁶ Thus, gender, menopausal status, and stressful triggers are not mandatory features and are not included in our HFA diagnostic criteria.

Patients with Takotsubo syndrome typically present with acute chest pain of cardiac origin (angina), breathlessness, and palpitations due to sinus tachycardia or arrhythmia; in more severe cases, pre-syncope or syncope due to ventricular tachyarrhythmias, severe left ventricular outflow tract obstruction (LVOTO), or

cardiogenic shock may be present. Patients may describe a wave of pressure from the chest to the neck and into the head, consistent with the acute catecholamine and hypertensive surge and frequently associated with diaphoresis and heightened anxiety.

Such patients should prompt urgent clinical evaluation and rapid acquisition of a resting 12-lead ECG. These findings should activate an ACS treatment pathway according to the ESC guidelines and, where appropriate, urgent coronary angiography⁶⁰ (see *Diagnostic algorithm*). Coronary computed tomography angiography (CCTA) may be considered in stable cases, particularly if the patient is pain free and cardiac imaging (e.g. echocardiography) shows typical features of Takotsubo syndrome.⁶¹

Once the diagnosis of Takotsubo syndrome is suspected in the catheterization laboratory, early cardiac imaging and assessment of cardiac biomarkers can help exclude MI and further stratify risk. Given the spectrum of clinical and anatomical patterns, the presence or absence of stressful triggers, and the potential presence of CAD or prodromal viral illnesses, borderline cases exist (see *Diagnostic algorithm*). In such cases, CMR imaging with late gadolinium enhancement (LGE) may be helpful.^{35,36} CMR is also complementary to echocardiography to detect complications and aid risk stratification, and has better sensitivity for detecting LV apical thrombus.

Secondary Takotsubo syndrome in specific clinical settings

Takotsubo syndrome can complicate a wide variety of acute medical and surgical conditions, including elective non-cardiac procedures (see 'Secondary Takotsubo syndrome' and *Table 1*). Iatrogenic causes during catecholamine administration (e.g. dobutamine stress echocardiography) have also been reported. Therefore, clinicians should be alert to Takotsubo syndrome in numerous clinical settings, including the acute medical unit, endocrinology ward, neurology ward, anaesthetic room, intensive care units (including the neuro-intensive care unit), obstetric unit, and psychiatric ward.

Takotsubo syndrome can be fatal because of mechanisms discussed below (see 'Complications and acute prognosis'). Many of these complications can be readily detected post-mortem in a confirmed case of Takotsubo syndrome. More difficult is the case of sudden non-hospital cardiac death in a patient with a stressful precipitant and a structurally normal heart and coronary arteries.⁶² These cases may have medico-legal or criminal implications, for example where sudden death occurs during restraint in police custody or in the psychiatric department. A more precise set of histopathological criteria is needed to help in post-mortem evaluation and diagnosis of Takotsubo syndrome as a cause of stress-induced sudden death.

Diagnostic investigations

Biomarkers

Cardiac troponin measured by conventional assays (not high sensitivity) is elevated in >90% of patients with Takotsubo syndrome.

However, the rise in serum troponin or creatinine kinase is disproportionately low relative to the extent of RVMA and cardiac dysfunction (i.e. widespread segmental akinesia/hypokinesia of >5 segments and frequently >9 segments in the 17-segment model).⁴⁸

During the acute phase of Takotsubo syndrome, serum cardiac natriuretic peptides (BNP or NT-proBNP) are almost always elevated, frequently to extremely high levels that correlate more closely with the degree of ventricular wall motion abnormality.^{63–66} The limited evidence to date suggests that BNP and NT-proBNP are more useful diagnostic biomarkers than troponin, and it is recommended that they be measured in all suspected cases if the assay is available. Since normal levels are extremely rare in Takotsubo syndrome, an elevated natriuretic peptide level is included in the new diagnostic criteria (Box 1). NT-proBNP is a valuable marker of myocardial deterioration and recovery. Low NT-proBNP at admission may reliably indicate a favourable prognosis and hence is included in our proposed risk stratification criteria (Box 4).

Other biomarkers have been reported in research studies but are not currently recommended in routine practice. Serum catecholamines (epinephrine, norepinephrine, and dopamine), neuropeptide-Y, and serotonin are typically elevated in Takotsubo syndrome.⁵³ Catecholamine levels are two to three times higher in patients with Takotsubo syndrome than in those with acute MI (Killip class III) at admission. This finding was reinforced by another study, although not all patients presented with elevated serum catecholamines.^{5,67} In a recent study, the profile of circulating microRNAs (small non-coding RNA sequences) differed in Takotsubo syndrome and STEMI patients,⁶⁸ supporting a different pathophysiology and the potential for developing future diagnostic biomarkers.

Electrocardiography

Abnormalities on ECG are present in >95% of Takotsubo syndrome patients during the acute phase.^{7,48,69–71} Daily ECGs are helpful, as a typical evolution has now been defined, and the potential for worsening of the QT interval is important in risk stratification and may help distinguish Takotsubo syndrome from STEMI.⁷² However ECG criteria alone are not sufficient to differentiate Takotsubo syndrome from STEMI.⁷³

The ECG abnormalities during the acute phase (<12 h) are ST-segment elevation, ST-segment depression, new LBBB, and sometimes Q-waves, with deep and widespread T-wave inversion and significant QT prolongation developing 24–48 h after the onset of symptoms or the precipitating stressful trigger (when present).⁷⁰ If presentation is delayed, T-wave inversion and QTc prolongation without ST segment elevation might be observed. The QTc prolongation is often pronounced (>500 ms), predisposing to torsades de pointes and ventricular fibrillation.^{17,70} Significant QTc prolongation is seldom seen in STEMI caused by coronary occlusion and may help to differentiate the two conditions retrospectively; however, it should not be used for prospective diagnosis. A minority of Takotsubo syndrome patients may present with a normal ECG, but this is atypical.

Box 4 Heart Failure Association risk stratification in Takotsubo syndrome

Risk factor	Higher risk	Lower risk
MAJOR RISK FACTORS		
Age	≥75 years	See minor risk factors ^a
Systolic BP	<110 mmHg	≥110 mmHg
Clinical pulmonary oedema ^b	Present	Absent
Unexplained syncope, VT or VF	Present	Absent
LVEF	<35%	See minor risk factors ^a
LVOTO	≥40 mmHg	Absent or <40 mmHg
Mitral regurgitation ^c	Present	Absent
Apical thrombus	Present	Absent
New VSD or contained LV wall rupture	Present	Absent
MINOR RISK FACTORS		
Age	70–75 years	<70 years
ECG		
QTc	≥500 ms	<500 ms
Pathological Q waves	Present	Absent
Persistent ST elevation ^d	Present	Absent
LVEF	35–45%	≥45%
Physical stressor	Present	Absent
Natriuretic peptides		
BNP	≥600 pg/mL	<600 pg/mL
NT-proBNP	≥2000 pg/mL	NT-proBNP <2000 pg/mL
Bystander obstructive CAD	Present	Absent
Biventricular involvement	Present	Absent

BP, blood pressure; LVOTO, left ventricular outflow tract obstruction; VF, ventricular fibrillation; VSD, ventricular septal defect; VT, ventricular tachycardia.

^aSee minor criteria regarding LVEF in the absence of major criteria.

^bLower zone (basal) pulmonary rales on clinical examination or evidence on chest X-ray.

^cModerate or severe mitral regurgitation.

^d≥3 days.

Coronary angiography and left ventriculography

Most Takotsubo syndrome patients should have urgent coronary angiography to exclude STEMI or NSTEMI because they present with cardiac chest pain and have ST elevation or other changes that could be interpreted as an ACS. In Takotsubo syndrome, the epicardial coronary arteries are typically normal and unobstructed; however, given the predilection for older patients, bystander CAD can be present. If so, it is important to consider whether the CAD is sufficient to cause the degree or pattern of LV dysfunction. Several studies reviewing cohorts of Takotsubo syndrome patients report bystander CAD in up to 10% of cases.^{74,75} Although not causative, bystander CAD is a risk factor for more severe heart failure during the acute episode (Box 4). Intravascular ultrasound studies have demonstrated that plaque rupture or intracoronary thrombosis is not present in Takotsubo syndrome.⁷⁶ Once causative coronary occlusion, including acute plaque rupture, thrombus formation, and coronary dissection, has been excluded, ventriculography should be performed unless there is a contraindication, since ventriculography will frequently be diagnostic for Takotsubo syndrome. This is important as the wall motion abnormalities may recover in hours and may be missed if imaging is delayed. The typical pattern of wall motion abnormality is the apical and mid-wall hypokinesis that earned this condition its original 'Takotsubo' label. However, other anatomical variants may occur (see 'Anatomical variants'; Figure 1; Table 2).

Echocardiography

Transthoracic echocardiography with colour and tissue Doppler should be the first non-invasive imaging technique to verify a suspected diagnosis of Takotsubo syndrome. Transthoracic echocardiography can assess LV morphology and function, identify anatomic variants, detect potential complications (e.g. LVOTO, mitral regurgitation, RV involvement, thrombus formation, and cardiac rupture), and monitor recovery.^{77–79} Key echocardiographic features during the acute phase consist of a large area of dysfunctional myocardium extending beyond the territory of a single coronary artery and usually characterized by symmetrical regional abnormalities involving the mid-ventricular segments of the anterior, inferior, and lateral walls (a circumferential pattern).⁷⁷ Among 227 patients enrolled in the Takotsubo Italian Network, low LVEF, elevated E/e' ratio, reversible moderate-to-severe mitral regurgitation, and age ≥ 75 years correlated independently with major adverse events (acute heart failure, cardiogenic shock, and in-hospital death).⁸⁰

Cardiac magnetic resonance

Cardiac magnetic resonance provides 3D anatomical information that can distinguish Takotsubo syndrome from other cardiac diseases and can help to elucidate its cause and pathophysiology.³⁵ It can accurately assess both LV and RV regional function and demonstrate the typical patterns of RWMA (Figure 1; Table 2). Takotsubo syndrome involves the right ventricle in up to one-third of patients,

and CMR often provides more complete views of the right ventricle than echocardiography.³⁵ CMR is superior to echocardiography in detecting apical LV thrombi, and patients with large areas of apical akinesia may benefit from CMR if echocardiography is unclear.⁸¹

During the acute phase of Takotsubo syndrome, T2-weighted CMR shows oedema of the LV myocardium as high signal intensity, with a diffuse or transmural distribution consistent with the wall motion abnormality. These features help distinguish Takotsubo syndrome from myocarditis and acute MI.^{25–28,82}

Typically, LGE is usually absent in Takotsubo syndrome and its absence is an important distinguishing feature from MI.³⁵ It is controversial, however, whether minor LGE may be present in some patients with Takotsubo syndrome during the acute phase but absent at follow-up CMR. The frequency of LGE depends on the threshold of signal intensity used to define its presence.^{83,84} Atypical cases with small areas of persistent apical transmural LGE have been reported.

If available, CMR should be considered in all patients with suspected Takotsubo syndrome in the acute phase (within 7 days). If availability is limited, it should be reserved for borderline and indeterminate cases (see *Diagnostic algorithm*). It is also useful to confirm recovery of ventricular function on follow-up and to exclude MI or other conditions that can mimic acute Takotsubo syndrome.

Coronary computed tomography angiography

In diagnosing Takotsubo syndrome, it is essential to exclude coronary occlusion and significant coronary stenosis. This evaluation is usually done invasively, as the patient typically presents with a clinical picture closely resembling that of acute MI. However, for a delayed presentation (>48 h after chest pain starts and the patient is pain free at the time of presentation) or for retrospective evaluation of a patient with the typical history of Takotsubo syndrome weeks or months previously, coronary stenoses can also be excluded by CCTA (Box 4). Acquiring information throughout the cardiac cycle (spiral or helical acquisition mode) during the acute phase can also demonstrate the typical pattern of systolic dysfunction but at the price of a higher radiation exposure.⁸⁵

Currently there is no evidence for delaying invasive coronary angiography in patients with ongoing acute chest pain and acute ECG changes. The ESC guidelines for STEMI or ACS should be followed until culprit CAD has been excluded.^{60,86}

Radionuclide imaging

The role of radionuclide imaging in the diagnosis and management of Takotsubo syndrome is undetermined. When CMR is unavailable, myocardial perfusion scintigraphy may help exclude infarction in uncertain cases, and there are reports of normal or mildly reduced perfusion in the dysfunctional segments, but out of keeping with the scale of contractile dysfunction.^{87–89}

Iodine-123 meta-iodo-benzyl-guanidine (mIBG) has been used to image myocardial sympathetic nerve terminal activity and to

detect adrenal or ectopic pheochromocytoma, which may be clinically relevant in these patients, although its precise role remains to be determined. During the acute phase, there is reduced mIBG in the dysfunctional myocardial segments, consistent with a regional disturbance of sympathetic neuronal activity.^{87,89} The abnormalities can persist for several months, and mIBG scintigraphy may have a role in cases without a diagnosis or when the presentation is remote from an acute episode (Box 4). Ideally, mIBG imaging should be combined with myocardial perfusion scintigraphy to exclude infarction; it is unknown whether persisting innervation abnormalities or increased mIBG washout, reflecting increased sympathetic tone, provides prognostic information.

Cardiac positron emission tomography using [¹⁸F]2-fluoro-deoxy-glucose has shown abnormal glucose metabolism in the context of normal myocardial perfusion in patients with Takotsubo syndrome; however, it currently has been used only in a research context.^{88,90}

Complications and acute prognosis

Takotsubo syndrome has generally been regarded as a relatively benign disease with rapid recovery of LV function. However, growing evidence suggests it is a more serious acute cardiac disorder with a variety of complications in ~52% of patients (Table 3).^{80,91,92}

Acute heart failure

Systolic heart failure is the most common complication in the acute phase of Takotsubo syndrome, occurring in 12–45% of cases.^{4,6,7,17,80,92} Independent predictors of acute heart failure are advanced age, low LVEF at presentation, higher admission and peak troponin levels, and a physical stressor preceding the onset of symptoms. Mechanical ventilation, inotropic support, and intra-aortic balloon pumping have been required in a substantial number of cases (28, 38, and 17%, respectively).⁹³ In some patients, pulmonary oedema due to acute LV dysfunction is exacerbated by mitral regurgitation, LVOTO, or both.

Left ventricular outflow tract obstruction

During the acute phase, a dynamic intraventricular pressure gradient due to mitral valve systolic anterior motion may develop as a consequence of myocardial stunning of the apical segments and hypercontraction of the basal LV myocardium. Significant LVOTO with gradients of 20–140 mmHg have been observed in 10–25% of patients, often accompanied by mitral regurgitation.^{7,80,94} A mid-ventricular or LVOTO gradient >25 mmHg is considered haemodynamically significant, and a gradient ≥40 mmHg is a high-risk factor. Abnormal Q waves, hypotension, and cardiogenic shock are more frequent in these patients. Use of inotropic drugs or nitrates may exacerbate LVOTO, whereas beta-blockade with propranolol decreases the gradient.^{95,96} Normally LVOTO resolves spontaneously over a few days.

Mitral regurgitation

Acute mitral regurgitation is another potentially serious complication, occurring in 14–25% of patients.^{97,98} LVEF is lower and pulmonary artery pressure is higher in patients with significant regurgitation, who present more often with acute heart failure or cardiogenic shock. Two independent mechanisms may cause acute mitral regurgitation: systolic anterior motion of the mitral valve in association with dynamic LVOTO and apical tethering of the subvalvular mitral valve apparatus.^{98,99} In most cases, the mitral regurgitation decreases as LV function returns to normal, although recovery may be slower than in patients without acute mitral regurgitation.

Cardiogenic shock

Cardiogenic shock, primarily due to acute LV dysfunction, occurs in 4–20% of patients with Takotsubo syndrome and may be exacerbated by RV involvement, LVOTO, or acute mitral regurgitation. Echocardiography may identify the mechanism and help guide therapy. The mortality due to cardiogenic shock in Takotsubo syndrome is high (17–30%).^{6,80,91,92,100}

Arrhythmias

Arrhythmias are common in patients with Takotsubo syndrome. New AF has been reported in 5–15% of cases.^{6,92,101,102} This arrhythmia further reduces cardiac output and is often associated with the onset of heart failure. Ventricular arrhythmias occur in 4–9% of patients during the acute phase of the syndrome,^{6,92,101–103} causing cardiac arrest in 4–6% of cases. In rare instances, ventricular arrhythmias have been documented weeks after the first manifestation of Takotsubo syndrome, when LV function had already normalized. Bradycardia due to atrioventricular block and asystole has also been described.⁹²

Thrombus formation

Thrombus in the akinetic ventricular apex is observed in 2–8% of Takotsubo syndrome patients, occasionally resulting in stroke or arterial embolism.^{92,104,105} Best visualized by CMR imaging in early post-contrast acquisition sequences, most thrombi develop 2–5 days after symptom onset, when LV function is still depressed. However, new thrombus formation and subsequent embolism have also been described 14 days after symptom onset, when LV systolic function had already returned to normal. LV thrombi may resolve with 2 weeks of therapeutic anticoagulation, but a longer course (usually 3 months) should be considered, and follow-up imaging is advisable to confirm recovery of apical contractile function.¹⁰⁶ Prophylactic anticoagulation in higher risk Takotsubo syndrome cases has an as yet undetermined role but may be considered (see *Management algorithm* for higher risk individuals).

Pericardial effusion

Acute pericarditis with recurrent chest pain, reappearance of ST-segment elevation, and a small amount of pericardial

effusion has been observed in some patients during the recovery phase of Takotsubo syndrome.¹⁰⁷ CMR imaging early after admission has detected small pericardial effusions in ~43% of patients. Pericardial tamponade requiring pericardiocentesis is rare (0.05%).¹⁰⁸

Ventricular wall rupture

Serious mechanical complications, including ventricular free wall rupture or interventricular septal perforation, are rare (<1%); they occur 2–8 days after symptom onset, often with persistent ST elevation.^{92,109,110} A high outflow tract gradient may favour rupture of the LV free wall. One case of RV rupture has been described. Interventricular septum perforation and acquired ventricular septal defect can complicate Takotsubo syndrome and may be successfully treated by surgery.^{111,112}

Right ventricular involvement

Patients with biventricular involvement generally have a more severe clinical course. RV involvement assessed by echocardiography or magnetic resonance imaging has been reported (18–34% cases) and is associated with older age, lower LVEF, a higher frequency of heart failure, pleural effusion, and a longer hospital stay.^{92,113} Rarely, a pressure gradient or an apical thrombus may be present in the right ventricle.

Mortality during the acute episode

In large studies and registries of Takotsubo syndrome patients, the in-hospital mortality rate is 2–5%; death is mainly caused by refractory cardiogenic shock or ventricular fibrillation.^{80,91,92} In a meta-analysis of 2120 patients in 37 studies, the in-hospital mortality rate was 4.5%,¹¹⁴ consistent with the 4.2% in-hospital mortality reported in the large NIS-USA Takotsubo syndrome cohorts.^{46,47}

Recurrence

Data on recurrence of Takotsubo syndrome are limited by the relatively short observation period in most studies. Five-year recurrence rates of 5–22% have been reported, with the second episode occurring 3 months to 10 years after the first.^{4,6,22,100} Recurrence of a different anatomical variant has been reported. Prognosis should be individualized according to the likelihood of recurrence, the triggering event, and co-existing medical conditions. If a patient has a recurrence, long-term clinical follow-up should be considered (see *Management algorithm*).

Long-term prognosis

There are conflicting reports and data regarding the long-term survival of patients after their initial episode of Takotsubo syndrome. In two studies, 4-year survival was not different from that of an age- and gender-matched population.^{115,116} However, in two other

studies, survival at 3 years was significantly lower than that of a matched general population.^{100,117} In the prospective SWEDEHEART registry, 3-year mortality was similar to that of NSTEMI and STEMI controls, and these results have recently been confirmed by data from the INTER-TAK registry.^{91,118} Excess mortality occurs predominantly in the first 4 years after diagnosis and is related to non-cardiac illnesses such as malignancy.^{116,119} Data on the long-term prognosis of patients with Takotsubo syndrome are limited.

Most patients recover rapidly after the acute episode and have no symptoms. However, there is increasing evidence that physiological abnormalities persist after resting contractile abnormalities have returned to normal ‘macroscopically’, and some patients have persistent cardiac symptoms after the acute episode,¹¹⁶ including angina, exertional breathlessness, palpitation, and a tremulous anxiety state, perhaps reflecting heightened sympathetic tone. Although the coronary arteries are unobstructed and ventricular function has recovered macroscopically, it is helpful to document objective evidence of ongoing cardiac abnormalities to reassure the patient and to guide treatment. Twenty-four-hour Holter ECG monitors to identify atrial arrhythmias or inappropriate sinus tachycardia (continuous or paroxysmal) may be helpful, and 24-h ambulatory blood pressure monitoring may detect transient and inappropriate hypertensive episodes. Persistent ECG changes and sometimes other evidence of autonomic disturbance can provide objective evidence and exclude non-cardiac explanations for ongoing symptoms. The absolute frequency of incomplete recovery is not well reported, and management of these patients requires specialist care.

Clinical management (see *Diagnostic algorithm and Management algorithm*)

General considerations

There are no randomized clinical trials to support specific treatment recommendations in Takotsubo syndrome. A key feature of Takotsubo syndrome is recovery of normal cardiac function. The major objective of in-hospital treatment should be supportive care to sustain life and to minimize complications during recovery. In mild cases, no treatment or a short course of limited medical therapy may be sufficient. In severe cases complicated by progressive circulatory failure and cardiogenic shock, early mechanical support should be considered as a ‘bridge-to-recovery’.

Diagnostic and management algorithms have been generated to help guide clinical decision-making. Risk stratification is essential to select treatment for patients at greatest risk of complications and to minimize interventions in patients at low risk where evidence for treatment is lacking. Given the lack of evidence from randomized controlled trials, the diagnostic and management algorithms are based on expert consensus and require validation in prospective trials. One over-riding consideration in a condition with a high rate of functional recovery is to respect the fundamental ethical principle in medicine: *primum non nocere* (first, do no harm).

Once the diagnosis is confirmed, it may be helpful to enquire about previous episodes of unexplained chest pain, and in particular hospital admissions for chest pain or MI. In some cases, the index presentation is clearly a recurrence of Takotsubo syndrome (see 'Prevention of recurrence').

In diagnosing borderline cases, it may be helpful to review the history to identify stressful triggers or co-existing medical conditions that may lead to sudden rises in sympathetic neural activity and systemic catecholamine levels. If the diagnosis is still uncertain, cardiac mIBG may be considered to evaluate regional myocardial sympathetic innervation and tone. It may be necessary to reserve judgement until follow-up imaging at 3 months confirms recovery of any RWMA present during the acute phase and clarifies the presence or absence of permanent LGE by CMR.

Risk stratification

Takotsubo syndrome has been generally regarded as a relatively benign disease with rapid recovery of LV function. However, a variety of complications occur in ~52% of the patients (Table 3).^{80,91,92} After diagnosis, we recommend that patients with Takotsubo syndrome be triaged according to the risk stratification system shown in Box 4 and the *Management algorithm*. Higher risk is defined as the presence of at least one major or two minor risk factors, with clinical judgement based on their severity.

Given the high risk of complications, where possible all patients with Takotsubo syndrome should be admitted to a coronary care unit or high-dependency unit with ECG monitoring for the first 24 h while the investigations and risk stratification are completed. Patients considered at higher risk of in-hospital mortality should be monitored in a high-dependency or coronary care unit. Patients at lower risk may be transferred to wards with lower levels of monitoring and potentially discharged early. Risk is a continuous variable and may change as new risk factors are identified. This risk stratification system is a clinical tool to guide clinicians caring for patients with Takotsubo syndrome. However, given the absence of randomized trial evidence, it does not replace clinical judgement. Validation of the risk stratification algorithm requires a prospective study, and therefore this proposal is currently based on expert opinion (level of evidence C).

Management of lower risk cases of Takotsubo syndrome

In milder cases with an LVEF >45% and no complications, the patient may be considered for early discharge from hospital. Before discharge, however, a review of medication is recommended, as many patients will have been started on treatment for ACS before coronary angiography, and indications for antiplatelet agents and statins should be reviewed. If LVEF is 35–45% but the patient is otherwise at lower risk, heart failure medications including beta-blockers should be considered. In pre-clinical studies, metoprolol and carvedilol have been beneficial, and these beta-blockers could be used unless contraindicated (e.g. reversible airways disease).^{120,121} Some experts suggest that vasoactive drugs,

including ACE inhibitors, should be avoided in patients with normal cardiac output, as some Takotsubo syndrome patients may have altered peripheral sympathetic nerve activity associated with low peripheral vascular resistance.

Takotsubo syndrome patients in the lower risk category should be followed for 3–6 months after discharge. The follow-up should include review of medications and cardiac imaging to confirm recovery of the RWMA.

Management of higher risk cases of Takotsubo syndrome

General considerations

Takotsubo syndrome cases meeting the criteria for higher risk should be monitored in a level 2 environment (e.g. coronary care unit or high-dependency unit) with continuous ECG monitoring and access to resuscitation equipment for at least 72 h after presentation, when risk of life-threatening complications is greatest.⁹² The opinion of a specialist (e.g. cardiologist with a special interest in heart failure) should be sought where available. Patients with decreased cardiac output should be considered for regular echocardiographic monitoring. Cessation of drugs with sympathomimetic properties is advised (e.g. catecholamines, beta2-agonists). Beta-blockers may be considered in haemodynamically stable patients and in patients with atrial or ventricular tachyarrhythmias. In patients with haemodynamically significant LVOTO (LVOTO >40 mmHg and systolic blood pressure <110 mmHg), treatment with a beta-blocker or selective alpha1-agonist (e.g. phenylephrine) should be considered. Short-acting intravenous beta-blockers are preferred acutely, providing no contraindications exist. If any clinical features suggest pheochromocytoma, appropriate diagnostic studies should be performed before beta-blocker treatment is started.

In patients with Takotsubo syndrome complicated by cardiogenic shock, continuous haemodynamic monitoring may help guide treatment selection. In more severe cases of cardiogenic shock with progressive end-organ dysfunction, avoidance or withdrawal of exogenous catecholamines is recommended, as they probably exacerbate or prolong the acute phase. Treatment options include mechanical support for acute cardiogenic shock, such as temporary LV assist devices (LVADs) and extracorporeal membrane oxygenation (ECMO) (see below), or, if those options are not available, low-dose levosimendan infusion as a catecholamine-sparing positive inotrope. No evidence currently exists to guide treatment choice in these complex patients, and new trial evidence is required. Expert consensus suggests that unstable patients with low cardiac output and cardiogenic shock be managed in a high-dependency unit (level 2) or intensive care unit (level 3) and that early LVAD or ECMO support be considered. The use of inotropes (e.g. dobutamine, norepinephrine, epinephrine, dopamine, milrinone, and isoproterenol) should be generally regarded as contraindicated in Takotsubo syndrome,¹²² as further activation of catecholamine receptors or their downstream molecular pathways might worsen the clinical status and prognosis of patients with Takotsubo syndrome and cardiogenic shock.^{120,123,124}

Mechanical support

Intra-aortic balloon counterpulsation (IABP) has been used to treat cardiogenic shock due to Takotsubo syndrome. However, in light of recent neutral data from the IABP-SHOCK II trial and the fact that IABP may worsen dynamic LVOTO, the consensus viewpoint is to avoid use of IABP in Takotsubo syndrome patients. If a patient with primary Takotsubo syndrome is deteriorating and has a low cardiac output, cardiogenic shock, and progressive multiorgan failure, specialist advice about ECMO or LVAD as a bridge-to-recovery is recommended, as there is an excellent chance that ventricular function will recover fully.^{125–128} In cases of secondary Takotsubo syndrome complicated by cardiogenic shock, the nature, severity, and prognosis of the underlying medical condition will determine whether mechanical cardiac support is warranted during the acute phase.

Levosimendan

The role of levosimendan is more controversial, with mixed expert opinion based on pre-clinical and limited clinical experience.^{120,129–133} In the absence of access to emergency mechanical support, levosimendan may be preferable to other inotropes such as dobutamine and epinephrine in patients who have advancing cardiogenic shock and multiorgan failure. Prospective randomized studies are required to assess the safety and efficacy of levosimendan in patients with Takotsubo syndrome and acute heart failure.

Access to all these advanced care options may vary and depend upon local expertise.

Preventing thrombo-embolism

Takotsubo syndrome may be associated with blood hypercoagulability reflecting the vasoconstrictor, platelet activation, or prothrombotic effects of high catecholamine levels.¹³⁴ Thromboembolism is a complication in ~4% of Takotsubo syndrome patients. Many patients with Takotsubo syndrome will initially receive antithrombotic treatment for suspected STEMI including dual antiplatelet therapy (aspirin and P2Y₁₂ receptor antagonists) and unfractionated or low-molecular-weight heparin. Once MI is excluded, consensus supports withdrawal of P2Y₁₂ receptor antagonists (clopidogrel, prasugrel, and ticagrelor).

Oral anticoagulation is recommended if intraventricular thrombus is detected in a patient with Takotsubo syndrome in the absence of high bleeding risk. Apical thrombus resolution and LV function recovery should be documented before anticoagulation is withdrawn. The role of prophylactic anticoagulation remains to be determined. Therapeutic low-molecular-weight heparin should be considered in cases with extensive segmental akinesia or atrial fibrillation.

Follow-up after hospital discharge

Regardless of the severity of their acute episode, all patients should be offered a follow-up assessment at 3–6 months. It should include

repeat cardiac imaging to confirm the resolution of the acute RWMA and ECG changes observed and to exclude MI by CMR with LGE if not performed during the acute admission and in borderline cases. A review of medication will ensure that any drug therapy for ACS has been stopped. If LV function has recovered, weaning from the ACE inhibitor and beta-blocker can be considered in the absence of other indications.

There is currently no evidence to guide the long-term management of patients after an episode of Takotsubo syndrome. Some patients have persistent cardiac symptoms after LVEF and RWMA have normalized,¹³⁵ including chest pain, palpitations, and exertional breathlessness. Further investigations to define the cause and treatment are advised, as ongoing cardiac abnormalities (e.g. microvascular perfusion abnormalities, atrial arrhythmias) may arise months or years after the acute episode.

Given the high risk of complications during the acute phase, patients with recurrent episodes of Takotsubo syndrome may warrant long-term follow-up to identify strategies to minimize or prevent further recurrence (see below).

Preventing recurrence

Prevention of recurrent Takotsubo syndrome has not been demonstrated in any study. Intuitively, beta-blockers may provide some protection against future catecholamine surges. However, recurrences have been reported in patients taking beta-blockers, and one meta-analysis found no impact of beta-blockers on the risk of recurrence, although recurrence was infrequent in both arms.^{136,137} Nevertheless, there may be a role for beta-blockers in selected patients, such as those with evidence of persistently elevated sympathetic tone, ongoing cardiac symptoms (not clinically recovered), and persistent anxiety and those with recurrent Takotsubo syndrome.

There is evidence that anxiety states are more frequent in some patients with Takotsubo syndrome. Given the high frequency of stressful triggers in cases of primary Takotsubo syndrome, the psychological response to stress is another potential therapeutic target. The benefit of psychological counselling and cognitive behavioural therapy remains to be determined, but they may have a role in selected cases of recurrence triggered by emotional stressors and in cases of confirmed anxiety disorder.

Late-presenting cases (Box 5)

Some patients have delayed access to medical care or request a retrospective assessment of 'troponin-positive chest pain episodes with normal coronary arteries' lacking a diagnosis. A careful review of the history and risk factor profile may alter the probability that the episode in question was an acute Takotsubo syndrome (Box 5). Review of ECGs and cardiac biomarkers, if available, may aid detection of the classical features that discriminate Takotsubo syndrome from ACS. Cardiac imaging, including echocardiography and CMR with LGE, helps exclude MI and other possible conditions. The role of cardiac mIBG is exploratory and may help demonstrate regional abnormalities of cardiac sympathetic innervation in

Box 5 Heart Failure Association management strategy for late-presenting Takotsubo syndrome cases

Late or retrospective review:

Review history

Review risk factors

Review ECGs

Review cardiac biomarker profile (serum natriuretic peptides and troponin) from acute episode

Consider:

Cardiac MRI + LGE (exclude MI, HCM)

CCTA (exclude obstructive CAD)

Cardiac mIBG

CCTA, coronary computed tomography angiography; HCM, hypertrophic cardiomyopathy; LGE, late gadolinium enhancement; MI, myocardial infarction; mIBG, iodine-123 meta-iodobenzyl-guanidine; MRI, magnetic resonance imaging.

a classical anatomical pattern and in the absence of infarction or alternative explanation.

Conclusion and future directions

Takotsubo syndrome is a fascinating acute heart failure syndrome, now increasingly recognized by the medical community. Many facets of this condition are incompletely understood or characterized, and current knowledge to guide optimal clinical management is limited. However, the increasing incidence and the high frequency of complications during the acute phase underpin the need to improve care pathways for patients with Takotsubo syndrome.

To date, clinical reports are mostly based on relatively small cohorts and case series. Therefore, the recommendations of this Position Statement reflect the consensus of expert opinion (level of evidence C). Randomized controlled trials are needed to identify optimal diagnostic and management strategies for Takotsubo syndrome. The potential for national and international registries to collect larger numbers of patients prospectively should aid understanding of the epidemiology and natural history. Takotsubo syndrome networks may also provide the infrastructure for research studies and, in particular, given the lack of current evidence-based treatments, for assessing novel therapeutic strategies. Individual hospitals may see no more than ~5–30 cases per annum, and broader networks are required to collect larger numbers of patients. Several countries have started to co-ordinate data collection in regional or national registries, and one international registry, the InterTAK registry (NCT01947621), has been launched to gather 10-year follow-up data on a large cohort of prospectively enrolled patients with confirmed Takotsubo syndrome.

This is the first Position Statement from the ESC Heart Failure Association for this acute heart failure syndrome. It will be updated when further advances in the understanding and management of Takotsubo syndrome are available, and particularly when results from randomized controlled trials are available to provide a stronger evidence base for clinical decision-making.

Conflict of interest: none declared.

References

1. Sato H, Tateishi H, Uchida T. Takotsubo-type cardiomyopathy due to multivessel spasm. In: Kodama K, Haze K, Hon M, eds. *Clinical Aspect of Myocardial Injury: From Ischemia to Heart Failure*. Tokyo: Kagakuhyouronsya Co.; 1990. p56–64.
2. Matsuoka H, Kawakami H, Koyama Y, Inoue K, Nishimura K, Saeki H, Ito T. 'Takotsubo' cardiomyopathy with a significant pressure gradient in the left ventricle. *Heart Vessels* 2000;**15**:203.
3. Tsuchihashi K, Ueshima K, Uchida T, Oh-mura N, Kimura K, Owa M, Yoshiyama M, Miyazaki S, Haze K, Ogawa H. Transient left ventricular apical ballooning without coronary artery stenosis: a novel heart syndrome mimicking acute myocardial infarction. *J Am Coll Cardiol* 2001;**38**:11–18.
4. Bybee KA, Kara T, Prasad A, Lerman A, Barsness GW, Wright RS, Rihal CS. Systematic review: transient left ventricular apical ballooning: a syndrome that mimics ST-segment elevation myocardial infarction. *Ann Intern Med* 2004;**141**:858–865.
5. Akashi YJ, Musha H, Kida K, Itoh K, Inoue K, Kawasaki K, Hashimoto N, Miyake F. Reversible ventricular dysfunction takotsubo cardiomyopathy. *Eur J Heart Fail* 2005;**7**:1171–1176.
6. Sharkey SW, Lesser JR, Zenovich AG, Maron MS, Lindberg J, Longe TF, Maron BJ. Acute and reversible cardiomyopathy provoked by stress in women from the United States. *Circulation* 2005;**111**:472–479.
7. Gianni M, Dentali F, Grandi AM, Sumner G, Hiralal R, Lonn E. Apical ballooning syndrome or takotsubo cardiomyopathy: a systematic review. *Eur Heart J* 2006;**27**:1523–1529.
8. Prasad A. Apical ballooning syndrome: an important differential diagnosis of acute myocardial infarction. *Circulation* 2007;**115**:e56–e59.
9. Wittstein IS. Acute stress cardiomyopathy. *Curr Heart Fail Rep* 2008;**5**:61–68.
10. Lyon AR, Rees PS, Prasad S, Poole-Wilson PA, Harding SE. Stress (Takotsubo) cardiomyopathy—a novel pathophysiological hypothesis to explain catecholamine-induced acute myocardial stunning. *Nat Clin Pract Cardiovasc Med* 2008;**5**:22–29.
11. Shao Y, Redfors B, Lyon AR, Rosengren A, Swedberg K, Omerovic E. Trends in publications on stress-induced cardiomyopathy. *Int J Cardiol* 2012;**157**:435–436.
12. Sharkey SW, Lesser JR, Maron MS, Maron BJ. Why not just call it tako-tsubo cardiomyopathy: a discussion of nomenclature. *J Am Coll Cardiol* 2011;**57**:1496–1497.
13. Maron BJ, Towbin JA, Thiene G, Antzelevitch C, Corrado D, Arnett D, Moss AJ, Seidman CE, Young JB. Contemporary definitions and classification of the cardiomyopathies: an American Heart Association Scientific Statement from the Council on Clinical Cardiology, Heart Failure and Transplantation Committee; Quality of Care and Outcomes Research and Functional Genomics and Translational Biology Interdisciplinary Working Groups; and Council on Epidemiology and Prevention. *Circulation* 2006;**113**:1807–1816.
14. Kawai S, Suzuki H, Yamaguchi H, Tanaka K, Sawada H, Aizawa T, Watanabe M, Tamura T, Umawatari K, Kawata M, Nakamura T, Yamanaka O, Okada R. Ampulla cardiomyopathy ('Takotsubo' cardiomyopathy)—reversible left ventricular dysfunction: with ST segment elevation. *Jpn Circ J* 2000;**64**:156–159.
15. Owa M, Aizawa K, Urasawa N, Ichinose H, Yamamoto K, Karasawa K, Kagoshima M, Koyama J, Ikeda S. Emotional stress-induced 'ampulla cardiomyopathy': discrepancy between the metabolic and sympathetic innervation imaging performed during the recovery course. *Jpn Circ J* 2001;**65**:349–352.
16. Mukherjee A, Sunkel-Laing B, Dewhurst N. 'Broken Heart' syndrome in Scotland: a case of Takotsubo cardiomyopathy in a recently widowed lady. *Scott Med J* 2013;**58**:e15–e19.
17. Schneider B, Athanasiadis A, Stollberger C, Pistner W, Schwab J, Gottwald U, Schoeller R, Gerecke B, Hoffmann E, Wegner C, Sechtem U. Gender differences in the manifestation of tako-tsubo cardiomyopathy. *Int J Cardiol* 2013;**166**:584–588.
18. Citro R, Rigo F, Previtali M, Ciampi Q, Canterin FA, Provenza G, Giudice R, Patella MM, Vriz O, Mehta R, Baldi C, Mehta RH, Bossone E. Differences in clinical features and in-hospital outcomes of older adults with tako-tsubo cardiomyopathy. *J Am Geriatr Soc* 2012;**60**:93–98.

19. Delgado GA, Truesdell AG, Kirchner RM, Zuzek RW, Pomerantsev EV, Gordon PC, Regnante RA. An angiographic and intravascular ultrasound study of the left anterior descending coronary artery in takotsubo cardiomyopathy. *Am J Cardiol* 2011;**108**:888–891.
20. Omerovic E. How to think about stress-induced cardiomyopathy?—Think 'out of the box'! *Scand Cardiovasc J* 2011;**45**:67–71.
21. Parodi G, Bellandi B, Del Pace S, Barchielli A, Zampini L, Velluzzi S, Carrabba N, Gensini GF, Antonucci D. Natural history of tako-tsubo cardiomyopathy. *Chest* 2011;**139**:887–892.
22. Prasad A, Lerman A, Rihal CS. Apical ballooning syndrome (Tako-Tsubo or stress cardiomyopathy): a mimic of acute myocardial infarction. *Am Heart J* 2008;**155**:408–417.
23. Kawai S, Kitabatake A, Tomoike H. Guidelines for diagnosis of takotsubo (apulla) cardiomyopathy. *Circ J* 2007;**71**:990–992.
24. Parodi G, Citro R, Bellandi B, Provenza G, Marrani M, Bossone E. Revised clinical diagnostic criteria for Tako-tsubo syndrome: the Tako-tsubo Italian Network proposal. *Int J Cardiol* 2014;**172**:282–283.
25. Iacucci I, Carbone I, Cannavale G, Conti B, Iampieri I, Rosati R, Sardella G, Frustaci A, Fedele F, Catalano C, Francone M. Myocardial oedema as the sole marker of acute injury in Takotsubo cardiomyopathy: a cardiovascular magnetic resonance (CMR) study. *Radiol Med* 2013;**118**:1309–1323.
26. Joshi SB, Chao T, Herzka DA, Zeman PR, Cooper HA, Lindsay J, Fuisz AR. Cardiovascular magnetic resonance T2 signal abnormalities in left ventricular ballooning syndrome. *Int J Cardiovasc Imaging* 2010;**26**:227–232.
27. Assomull RG, Lyne JC, Keenan N, Gulati A, Bunce NH, Davies SW, Pennell DJ, Prasad SK. The role of cardiovascular magnetic resonance in patients presenting with chest pain, raised troponin, and unobstructed coronary arteries. *Eur Heart J* 2007;**28**:1242–1249.
28. Friedrich MG, Sechtem U, Schulz-Menger J, Holmvang G, Alakija P, Cooper LT, White JA, Abdel-Aty H, Gutberlet M, Prasad S, Aletras A, Laissy JP, Paterson I, Filipchuk NG, Kumar A, Pauschinger M, Liu P. Cardiovascular magnetic resonance in myocarditis: a JACC White Paper. *J Am Coll Cardiol* 2009;**53**:1475–1487.
29. Santoro F, Ieva R, Spennati G, De Gennaro L, Correale M, Di Biase M, Brunetti ND. Tako-Tsubo cardiomyopathy in a teen girl with pheochromocytoma. *Int J Cardiol* 2012;**160**:e48–e49.
30. Naderi N, Amin A, Setayesh A, Pouraliakbar H, Mozaffari K, Maleki M. Pheochromocytoma-induced reverse tako-tsubo with rapid recovery of left ventricular function. *Cardiol J* 2012;**19**:527–531.
31. Cesaretti M, Ansaldo G, Varaldo E, Assalino M, Trotta M, Torre G, Borgonovo G. Tako-tsubo cardiomyopathy as initial presentation of pheochromocytoma. A clinical case. *Ann Ital Chir* 2010;**81**:439–443.
32. Lassnig E, Weber T, Auer J, Nomeyer R, Eber B. Pheochromocytoma crisis presenting with shock and tako-tsubo-like cardiomyopathy. *Int J Cardiol* 2009;**134**:e138–e140.
33. Spes C, Knape A, Mudra H. Recurrent tako-tsubo-like left ventricular dysfunction (apical ballooning) in a patient with pheochromocytoma—a case report. *Clin Res Cardiol* 2006;**95**:307–311.
34. Sanchez-Recalde A, Costero O, Oliver JM, Iborra C, Ruiz E, Sobrino JA. Images in cardiovascular medicine. Pheochromocytoma-related cardiomyopathy: inverted Takotsubo contractile pattern. *Circulation* 2006;**113**:e738–e739.
35. Eitel I, von Knobelsdorff-Brenkenhoff F, Bernhardt P, Carbone I, Muellerleile K, Aldrovandi A, Francone M, Desch S, Gutberlet M, Strohm O, Schuler G, Schulz-Menger J, Thiele H, Friedrich MG. Clinical characteristics and cardiovascular magnetic resonance findings in stress (takotsubo) cardiomyopathy. *JAMA* 2011;**306**:277–286.
36. Hagh D, Athanasiadis A, Papavassiliou T, Suselbeck T, Fluechter S, Mahrholdt H, Borggrefe M, Sechtem U. Right ventricular involvement in Takotsubo cardiomyopathy. *Eur Heart J* 2006;**27**:2433–2439.
37. Kurowski V, Kaiser A, von Hof K, Killermann DP, Mayer B, Hartmann F, Schunkert H, Radke PW. Apical and midventricular transient left ventricular dysfunction syndrome (tako-tsubo cardiomyopathy): frequency, mechanisms, and prognosis. *Chest* 2007;**132**:809–816.
38. Ennezat PV, Pesenti-Rossi D, Aubert JM, Rachenne V, Bauchart JJ, Auffray JL, Logeart D, Cohen-Solal A, Asseman P. Transient left ventricular basal dysfunction without coronary stenosis in acute cerebral disorders: a novel heart syndrome (inverted Takotsubo). *Echocardiography* 2005;**22**:599–602.
39. Van de Walle SO, Gevaert SA, Gheeraert PJ, De Pauw M, Gillebert TC. Transient stress-induced cardiomyopathy with an 'inverted takotsubo' contractile pattern. *Mayo Clin Proc* 2006;**81**:1499–1502.
40. Cacciotti L, Camastra GS, Beni S, Giannantoni P, Musaro S, Proietti I, De Angelis L, Semeraro R, Ansalone G. A new variant of Tako-tsubo cardiomyopathy: transient mid-ventricular ballooning. *J Cardiovasc Med* 2007;**8**:1052–1054.
41. Kurisu S, Inoue I, Kawagoe T, Ishihara M, Shimatani Y, Mitsuba N, Hata T, Nakama Y, Kisaka T, Kijima Y. Takotsubo-like transient biventricular dysfunction with pressure gradients. *Intern Med* 2005;**44**:727–732.
42. Novak G, Kross K, Follmer K, Brofferio A, Shirani J. Transient biventricular apical ballooning: a unique presentation of the 'broken heart'. *Clin Cardiol* 2007;**30**:355–358.
43. Abdulla I, Kay S, Mussap C, Nelson GI, Rasmussen HH, Hansen PS, Ward MR. Apical sparing in tako-tsubo cardiomyopathy. *Intern Med J* 2006;**36**:414–418.
44. Singh K, Parsaik A, Singh B. Recurrent takotsubo cardiomyopathy: variable pattern of ventricular involvement. *Herz* 2014;**39**:963–967.
45. Koeth O, Mark B, Zahn R, Zeymer U. Midventricular form of takotsubo cardiomyopathy as a recurrence 1 year after typical apical ballooning: a case report. *Cases J* 2008;**1**:331.
46. Deshmukh A, Kumar G, Pant S, Rihal C, Murugiah K, Mehta JL. Prevalence of Takotsubo cardiomyopathy in the United States. *Am Heart J* 2012;**164**:66–71.e1.
47. Brinjikji W, El-Sayed AM, Salka S. In-hospital mortality among patients with takotsubo cardiomyopathy: a study of the National Inpatient Sample 2008 to 2009. *Am Heart J* 2012;**164**:215–221.
48. Pilgrim TM, Wyss TR. Takotsubo cardiomyopathy or transient left ventricular apical ballooning syndrome: a systematic review. *Int J Cardiol* 2008;**124**:283–292.
49. Merli E, Sutcliffe S, Gori M, Sutherland GG. Tako-Tsubo cardiomyopathy: new insights into the possible underlying pathophysiology. *Eur J Echocardiogr* 2006;**7**:53–61.
50. Tranter MH, Wright PT, Sikkil MB, Lyon AR. Takotsubo cardiomyopathy: the pathophysiology. *Heart Fail Clin* 2013;**9**:187–196, viii–ix.
51. Redfors B, Shao Y, Ali A, Omerovic E. Are the different patterns of stress-induced (Takotsubo) cardiomyopathy explained by regional mechanical overload and demand:supply mismatch in selected ventricular regions? *Med Hypotheses* 2013;**81**:954–960.
52. Nef HM, Mollmann H, Akashi YJ, Hamm CW. Mechanisms of stress (Takotsubo) cardiomyopathy. *Nat Rev Cardiol* 2010;**7**:187–193.
53. Wittstein IS, Thiemann DR, Lima JAC, Baughman KL, Schulman SP, Gerstenblith G, Wu KC, Rade JJ, Bivalacqua TJ, Champion HC. Neurohumoral features of myocardial stunning due to sudden emotional stress. *N Engl J Med* 2005;**352**:539–548.
54. Abraham J, Mudd JO, Kapur NK, Klein K, Champion HC, Wittstein IS. Stress cardiomyopathy after intravenous administration of catecholamines and beta-receptor agonists. *J Am Coll Cardiol* 2009;**53**:1320–1325.
55. Kumar G, Holmes DR, Jr., Prasad A. 'Familial' apical ballooning syndrome (Takotsubo cardiomyopathy). *Int J Cardiol* 2010;**144**:444–445.
56. Pison L, De Vusser P, Mullens W. Apical ballooning in relatives. *Heart* 2004;**90**:e67.
57. Musumeci B, Saponaro A, Pagannone E, Proietti G, Mastromarino V, Conti E, Tubaro M, Volpe M, Autore C. Simultaneous Takotsubo syndrome in two sisters. *Int J Cardiol* 2013;**165**:e49–e50.
58. Ikutomi M, Yamasaki M, Matsusita M, Watari Y, Arashi H, Endo G, Yamaguchi J, Ohnishi S. Takotsubo cardiomyopathy in siblings. *Heart Vessels* 2014;**29**:119–122.
59. Summers MR, Prasad A. Takotsubo cardiomyopathy: definition and clinical profile. *Heart Fail Clin* 2013;**9**:111–122, vii.
60. Steg PG, James SK, Atar D, Badano LP, Blomstrom-Lundqvist C, Borger MA, Di Mario C, Dickstein K, Ducrocq G, Fernandez-Aviles F, Gershlick AH, Giannuzzi P, Halvorsen S, Huber K, Juni P, Kastrati A, Knuuti J, Lenzen MJ, Mahaffey KW, Valgimigli M, van 't Hof A, Widimsky P, Zaher D. ESC Guidelines for the management of acute myocardial infarction in patients presenting with ST-segment elevation. *Eur Heart J* 2012;**33**:2569–2619.
61. Otaño L, Zambrano JP, Fishman JE. Takotsubo cardiomyopathy: utility of cardiac computed tomography angiography for acute diagnosis. *J Thorac Imaging* 2011;**26**:W83–W85.
62. Liang JJ, Cha YM, Oh JK, Prasad A. Sudden cardiac death: an increasingly recognized presentation of apical ballooning syndrome (Takotsubo cardiomyopathy). *Heart Lung* 2013;**42**:270–272.
63. Madhavan M, Borlaug BA, Lerman A, Rihal CS, Prasad A. Stress hormone and circulating biomarker profile of apical ballooning syndrome (Takotsubo cardiomyopathy): insights into the clinical significance of B-type natriuretic peptide and troponin levels. *Heart* 2009;**95**:1436–1441.
64. Ahmed KA, Madhavan M, Prasad A. Brain natriuretic peptide in apical ballooning syndrome (Takotsubo/stress cardiomyopathy): comparison with acute myocardial infarction. *Coron Artery Dis* 2012;**23**:259–264.
65. Frohlich GM, Schoch B, Schmid F, Keller P, Sudano I, Luscher TF, Noll G, Ruschitzka F, Enseleit F. Takotsubo cardiomyopathy has a unique cardiac biomarker profile: NT-proBNP/myoglobin and NT-proBNP/troponin T ratios for the differential diagnosis of acute coronary syndromes and stress induced cardiomyopathy. *Int J Cardiol* 2012;**154**:328–332.

66. Nguyen TH, Neil CJ, Sverdlow AL, Mahadavan G, Chirkov YY, Kucia AM, Stansborough J, Beltrame JF, Selvanayagam JB, Zeitz CJ, Struthers AD, Frenneaux MP, Horowitz JD. N-terminal pro-brain natriuretic protein levels in takotsubo cardiomyopathy. *Am J Cardiol* 2011;**108**:1316–1321.
67. Morel O, Sauer F, Imperiale A, Cimarelli S, Blondet C, Jesel L, Trinh A, De Poli F, Ohlmann P, Constantinesco A, Bareiss P. Importance of inflammation and neurohumoral activation in Takotsubo cardiomyopathy. *J Card Fail* 2009;**15**:206–213.
68. Jaguszewski M, Osipova J, Ghadri JR, Napp LC, Widera C, Franke J, Fijalkowski M, Nowak R, Fijalkowska M, Volkman I, Katus HA, Wollert KC, Bauersachs J, Erne P, Luscher TF, Thum T, Templin C. A signature of circulating microRNAs differentiates takotsubo cardiomyopathy from acute myocardial infarction. *Eur Heart J* 2014;**35**:999–1006.
69. Ogura R, Hiasa Y, Takahashi T, Yamaguchi K, Fujiwara K, Ohara Y, Nada T, Ogata T, Kusunoki K, Yuba K, Hosokawa S, Kishi K, Ohtani R. Specific findings of the standard 12-lead ECG in patients with 'Takotsubo' cardiomyopathy: comparison with the findings of acute anterior myocardial infarction. *Circ J* 2003;**67**:687–690.
70. Kurisu S, Inoue I, Kawagoe T, Ishihara M, Shimatani Y, Nakamura S, Yoshida M, Mitsuba N, Hata T, Sato H. Time course of electrocardiographic changes in patients with tako-tsubo syndrome: comparison with acute myocardial infarction with minimal enzymatic release. *Circ J* 2004;**68**:77–81.
71. Sharkey SW. Electrocardiogram mimics of acute ST-segment elevation myocardial infarction: insights from cardiac magnetic resonance imaging in patients with tako-tsubo (stress) cardiomyopathy. *J Electrocardiol* 2008;**41**:621–625.
72. Kosuge M, Ebina T, Hibi K, Morita S, Okuda J, Iwahashi N, Tsukahara K, Nakachi T, Kiyokuni M, Ishikawa T, Umemura S, Kimura K. Simple and accurate electrocardiographic criteria to differentiate takotsubo cardiomyopathy from anterior acute myocardial infarction. *J Am Coll Cardiol* 2010;**55**:2514–2516.
73. Johnson NP, Chavez JF, Mosley WJ 2nd, Flaherty JD, Fox JM. Performance of electrocardiographic criteria to differentiate Takotsubo cardiomyopathy from acute anterior ST elevation myocardial infarction. *Int J Cardiol* 2013;**164**:345–348.
74. Gaibazzi N, Ugo F, Vignali L, Zoni A, Reverberi C, Gherli T. Tako-Tsubo cardiomyopathy with coronary artery stenosis: a case-series challenging the original definition. *Int J Cardiol* 2009;**133**:205–212.
75. Prevalenti M, Repetto A, Panigada S, Camporotondo R, Tavazzi L. Left ventricular apical ballooning syndrome: prevalence, clinical characteristics and pathogenetic mechanisms in a European population. *Int J Cardiol* 2009;**134**:91–96.
76. Haghi D, Roehm S, Hamm K, Harder N, Suselbeck T, Borggreffe M, Papavassiliu T. Takotsubo cardiomyopathy is not due to plaque rupture: an intravascular ultrasound study. *Clin Cardiol* 2010;**33**:307–310.
77. Citro R, Rigo F, Ciampi Q, D'Andrea A, Provenza G, Mirra M, Giudice R, Silvestri F, Di Benedetto G, Bossone E. Echocardiographic assessment of regional left ventricular wall motion abnormalities in patients with tako-tsubo cardiomyopathy: comparison with anterior myocardial infarction. *Eur J Echocardiogr* 2011;**12**:542–549.
78. Bossone E, Lyon A, Citro R, Athanasiadis A, Meimoun P, Parodi G, Cimarelli S, Omerovic E, Ferrara F, Limongelli G, Cittadini A, Salerno-Uriarte JA, Perrone Filardi P, Schneider B, Sechtem U, Erbel R. Takotsubo cardiomyopathy: an integrated multi-imaging approach. *Eur Heart J Cardiovasc Imaging* 2014;**15**:366–377.
79. Meimoun P, Clerc J, Vincent C, Flahaut F, Germain AL, Elmekies F, Zemir H, Luyckx-Bore A. Non-invasive detection of tako-tsubo cardiomyopathy vs. acute anterior myocardial infarction by transthoracic Doppler echocardiography. *Eur Heart J Cardiovasc Imaging* 2013;**14**:464–470.
80. Citro R, Rigo F, D'Andrea A, Ciampi Q, Parodi G, Provenza G, Piccolo R, Mirra M, Zito C, Giudice R, Patella MM, Antonini-Canterin F, Bossone E, Piscione F, Salerno-Uriarte J. Echocardiographic correlates of acute heart failure, cardiogenic shock, and in-hospital mortality in tako-tsubo cardiomyopathy. *JACC Cardiovasc Imaging* 2014;**7**:119–129.
81. Weinsaft JW, Kim HW, Crowley AL, Klem I, Shenoy C, Van Assche L, Brosnan R, Shah DJ, Velazquez EJ, Parker M, Judd RM, Kim RJ. LV thrombus detection by routine echocardiography: insights into performance characteristics using delayed enhancement CMR. *JACC Cardiovasc Imaging* 2011;**4**:702–712.
82. Thavandiranathan P, Walls M, Giri S, Verhaert D, Rajagopalan S, Moore S, Simonetti OP, Raman SV. Improved detection of myocardial involvement in acute inflammatory cardiomyopathies using T2 mapping. *Circ Cardiovasc Imaging* 2012;**5**:102–110.
83. Naruse Y, Sato A, Kasahara K, Makino K, Sano M, Takeuchi Y, Nagasaka S, Wakabayashi Y, Katoh H, Satoh H, Hayashi H, Aonuma K. The clinical impact of late gadolinium enhancement in Takotsubo cardiomyopathy: serial analysis of cardiovascular magnetic resonance images. *J Cardiovascular Cardiovasc Magn Reson* 2011;**13**:67.
84. Alter P, Figiel JH, Rominger MB. Increased ventricular wall stress and late gadolinium enhancement in Takotsubo cardiomyopathy. *Int J Cardiol* 2014;**172**:e184–e186.
85. Nance JW, Schoepf UJ, Ramos-Duran L. Tako-tsubo cardiomyopathy: findings on cardiac CT and coronary catheterisation. *Heart* 2010;**96**:406–407.
86. Hamm CW, Bassand J-P, Agewall S, Bax J, Boersma E, Bueno H, Caso P, Dudek D, Gielen S, Huber K, Ohman M, Petrie MC, Sonntag F, Uva MS, Storey RF, Wijns W, Zahger D, Bax JJ, Auricchio A, Baumgartner H, Ceconi C, Dean V, Deaton C, Fagard R, Funck-Brentano C, Hasdai D, Hoes A, Knuuti J, Kolh P, McDonagh T, Moulin C, Poldermans D, Popescu BA, Reiner Ž, Sechtem U, Sirnes PA, Torbicki A, Vahanian A, Windecker S, Windecker S, Achenbach S, Badimon L, Bertrand M, Botker HE, Collet J-P, Crea F, Danchin N, Falk E, Goudevens J, Gulba D, Hambrecht R, Herrmann J, Kastrati A, Kjeldsen K, Kristensen SD, Lancellotti P, Mehilli J, Merkely B, Montalescot G, Neumann F-J, Neyens L, Perkić J, Roffi M, Romeo F, Ruda M, Swahn E, Valgimigli M, Vrints CJ, Widimsky P. ESC Guidelines for the management of acute coronary syndromes in patients presenting without persistent ST-segment elevation: the Task Force for the management of acute coronary syndromes (ACS) in patients presenting without persistent ST-segment elevation of the European Society of Cardiology (ESC). *Eur Heart J* 2011;**32**:2999–3054.
87. Cimarelli S, Sauer F, Morel O, Ohlmann P, Constantinesco A, Imperiale A. Transient left ventricular dysfunction syndrome: patho-physiological bases through nuclear medicine imaging. *Int J Cardiol* 2010;**144**:212–218.
88. Yoshida T, Hibino T, Kako N, Murai S, Oguri M, Kato K, Yajima K, Ohte N, Yokoi K, Kimura G. A pathophysiologic study of tako-tsubo cardiomyopathy with F-18 fluorodeoxyglucose positron emission tomography. *Eur Heart J* 2007;**28**:2598–2604.
89. Ito K, Sugihara H, Kinoshita N, Azuma A, Matsubara H. Assessment of Takotsubo cardiomyopathy (transient left ventricular apical ballooning) using ^{99m}Tc-tetrofosmin, ^{123I}-BMIPP, ^{123I}-MIBG and ^{99m}Tc-PYP myocardial SPECT. *Ann Nucl Med* 2005;**19**:435–445.
90. Christensen TE, Bang LE, Holmvang L, Ghotbi AA, Lassen ML, Andersen F, Ihlemann N, Andersson H, Grande P, Kjaer A, Hasbak P. Cardiac Tc sestamibi SPECT and F FDG PET as viability markers in takotsubo cardiomyopathy. *Int J Cardiovasc Imaging* 2014;**30**:1407–1416.
91. Redfors B, Vedad R, Angerås O, Råmunddal T, Petursson P, Haraldsson I, Ali A, Dworeck C, Odenstedt J, Ioannes D, Libungan B, Shao Y, Albertsson P, Stone GW, Omerovic E. Mortality in takotsubo syndrome is similar to mortality in myocardial infarction—A report from the SWEDEHEART1 registry. *Int J Cardiol* 2015;**185**:282–289.
92. Schneider B, Athanasiadis A, Schwab J, Pistner W, Gottwald U, Schoeller R, Toepel W, Winter KD, Stellbrink C, Müller-Honold T, Wegner C, Sechtem U. Complications in the clinical course of tako-tsubo cardiomyopathy. *Int J Cardiol* 2014;**176**:199–205.
93. Madhavan M, Rihal CS, Lerman A, Prasad A. Acute heart failure in apical ballooning syndrome (TakoTsubo/stress cardiomyopathy): clinical correlates and Mayo Clinic risk score. *J Am Coll Cardiol* 2011;**57**:1400–1401.
94. Ohba Y, Takemoto M, Nakano M, Yamamoto H. Takotsubo cardiomyopathy with left ventricular outflow tract obstruction. *Int J Cardiol* 2006;**107**:120–122.
95. Yoshioka T, Hashimoto A, Tsuchihashi K, Nagao K, Kyuma M, Ooiwa H, Nozawa A, Shimoshige S, Eguchi M, Wakabayashi T, Yuda S, Hase M, Nakata T, Shimamoto K. Clinical implications of midventricular obstruction and intravenous propranolol use in transient left ventricular apical ballooning (Tako-tsubo cardiomyopathy). *Am Heart J* 2008;**155**:526.e1–e7.
96. Kyuma M, Tsuchihashi K, Shinshi Y, Hase M, Nakata T, Ooiwa H, Abiru M, Hikita N, Adachi T, Shoji T, Fujise Y, Shimamoto K. Effect of intravenous propranolol on left ventricular apical ballooning without coronary artery stenosis (ampulla cardiomyopathy): three cases. *Circ J* 2002;**66**:1181–1184.
97. Haghi D, Rohm S, Suselbeck T, Borggreffe M, Papavassiliu T. Incidence and clinical significance of mitral regurgitation in Takotsubo cardiomyopathy. *Clin Res Cardiol* 2010;**99**:93–98.
98. Parodi G, Del Pace S, Salvadori C, Carrabba N, Olivetto I, Gensini GF. Left ventricular apical ballooning syndrome as a novel cause of acute mitral regurgitation. *J Am Coll Cardiol* 2007;**50**:647–649.
99. Izumo M, Nalawadi S, Shiota M, Das J, Dohad S, Kuwahara E, Fukuoka Y, Siegel RJ, Shiota T. Mechanisms of acute mitral regurgitation in patients with takotsubo cardiomyopathy: an echocardiographic study. *Circ Cardiovasc Imaging* 2011;**4**:392–398.
100. Schultz T, Shao Y, Redfors B, Sverrisdottir YB, Ramunddal T, Albertsson P, Matejka G, Omerovic E. Stress-induced cardiomyopathy in Sweden: evidence for different ethnic predisposition and altered cardio-circulatory status. *Cardiology* 2012;**122**:180–186.
101. Syed FF, Asirvatham SJ, Francis J. Arrhythmia occurrence with takotsubo cardiomyopathy: a literature review. *Europace* 2011;**13**:780–788.

102. Pant S, Deshmukh A, Mehta K, Badheka AO, Tuliani T, Patel NJ, Dabhadkar K, Prasad A, Paydak H. Burden of arrhythmias in patients with Takotsubo Cardiomyopathy (apical ballooning syndrome). *Int J Cardiol* 2013;**170**: 64–68.
103. Murakami T, Yoshikawa T, Maekawa Y, Ueda T, Isogai T, Konishi Y, Sakata K, Nagao K, Yamamoto T, Takayama M. Characterization of predictors of in-hospital cardiac complications of takotsubo cardiomyopathy: multi-center registry from Tokyo CCU Network. *J Cardiol* 2014;**63**:269–273.
104. Kurisu S, Inoue I, Kawagoe T, Ishihara M, Shimatani Y, Nakama Y, Maruhashi T, Kagawa E, Dai K. Incidence and treatment of left ventricular apical thrombosis in Tako-tsubo cardiomyopathy. *Int J Cardiol* 2011;**146**:e58–e60.
105. de Gregorio C, Grimaldi P, Lentini C. Left ventricular thrombus formation and cardioembolic complications in patients with Takotsubo-like syndrome: a systematic review. *Int J Cardiol* 2008;**131**:18–24.
106. Korosoglou G, Haars A, Kuecherer H, Giannitsis E, Katus HA. Prompt resolution of an apical left ventricular thrombus in a patient with takotsubo cardiomyopathy. *Int J Cardiol* 2007;**116**:e88–e91.
107. Kim J, Laird-Fick HS, Alsara O, Gourineni V, Abela GS. Pericarditis in takotsubo cardiomyopathy: a case report and review of the literature. *Case Rep Cardiol* 2013;**2013**:917851.
108. Yeh RW, Yu PB, Drachman DE. Takotsubo cardiomyopathy complicated by cardiac tamponade: classic hemodynamic findings with a new disease. *Circulation* 2010;**122**:1239–1241.
109. Yoshida S, Miwa K, Matsubara T, Yasuda T, Inoue M, Teramoto R, Okada H, Kanaya H, Hayashi K, Konno T, Kawashiri MA, Yamagishi M. Stress-induced takotsubo cardiomyopathy complicated with wall rupture and thrombus formation. *Int J Cardiol* 2012;**161**:e18–e20.
110. Akashi YJ, Tejima T, Sakurada H, Matsuda H, Suzuki K, Kawasaki K, Tsuchiya K, Hashimoto N, Musha H, Sakakibara M, Nakazawa K, Miyake F. Left ventricular rupture associated with Takotsubo cardiomyopathy. *Mayo Clin Proc* 2004;**79**:821–824.
111. Izumi K, Tada S, Yamada T. A case of Takotsubo cardiomyopathy complicated by ventricular septal perforation. *Circ J* 2008;**72**:1540–1543.
112. Sakai K, Ochiai H, Katayama N, Nakamura K, Arataki K, Kido T, Iwamoto H, Nakamura S, Nakanishi T. Ventricular septal perforation in a patient with takotsubo cardiomyopathy. *Circ J* 2005;**69**:365–367.
113. Elesber AA, Prasad A, Bybee KA, Valeti U, Motiei A, Lerman A, Chandrasekaran K, Rihal CS. Transient cardiac apical ballooning syndrome: prevalence and clinical implications of right ventricular involvement. *J Am Coll Cardiol* 2006;**47**:1082–1083.
114. Singh K, Carson K, Shah R, Sawhney G, Singh B, Parsaik A, Gilutz H, Usmani Z, Horowitz J. Meta-analysis of clinical correlates of acute mortality in takotsubo cardiomyopathy. *Am J Cardiol* 2014;**113**:1420–1428.
115. Nunez-Gil IJ, Molina M, Bernardo E, Ibanez B, Ruiz-Mateos B, Garcia-Rubira JC, Vivas D, Feltes G, Luaces M, Alonso J, Zamorano J, Macaya C, Fernandez-Ortiz A. Tako-tsubo syndrome and heart failure: long-term follow-up. *Rev Esp Cardiol* 2012;**65**:996–1002.
116. Elesber AA, Prasad A, Lennon RJ, Wright RS, Lerman A, Rihal CS. Four-year recurrence rate and prognosis of the apical ballooning syndrome. *J Am Coll Cardiol* 2007;**50**:448–452.
117. Sharkey SW, Windenburg DC, Lesser JR, Maron MS, Hauser RG, Lesser JN, Haas TS, Hodges JS, Maron BJ. Natural history and expansive clinical profile of stress (tako-tsubo) cardiomyopathy. *J Am Coll Cardiol* 2010;**55**:333–341.
118. Templin C, Ghadri JR, Diekmann J, Napp LC, Bataiosu DR, Jaguszewski M, Cammann VL, Sarcon A, Geyer V, Neumann CA, Seifert B, Hellermann J, Schwyzer M, Eisenhardt K, Jenewein J, Franke J, Katus HA, Burgdorf C, Schunkert H, Moeller C, Thiele H, Bauersachs J, Tschope C, Schultheiss HP, Laney CA, Rajan L, Michels G, Pfister R, Ukena C, Bohm M, Erbel R, Cuneo A, Kuck KH, Jacobshagen C, Hasenfuss G, Karakas M, Koenig W, Rottbauer W, Said SM, Braun-Dullaeus RC, Cuculi F, Banning A, Fischer TA, Vasankari T, Airaksinen KE, Fijalkowski M, Rynkiewicz A, Pawlak M, Opolski G, Dworakowski R, MacCarthy P, Kaiser C, Osswald S, Galiuto L, Crea F, Dichtl W, Franz WM, Empen K, Felix SB, Delmas C, Lairez O, Erne P, Bax JJ, Ford I, Ruschitzka F, Prasad A, Lüscher TF. Clinical features and outcomes of Takotsubo (stress) cardiomyopathy. *N Engl J Med* 2015;**373**:929–938.
119. Burgdorf C, Kurowski V, Radke PW. Long-term prognosis of transient left ventricular ballooning syndrome and cancer. *Heart Lung* 2011;**40**:472.
120. Paur H, Wright PT, Sikkel MB, Tranter MH, Mansfield C, O'Gara P, Stuckey DJ, Nikolaev VO, Diakonov I, Pannell L, Gong H, Sun H, Peters NS, Petrou M, Zheng Z, Gorelik J, Lyon AR, Harding SE. High levels of circulating epinephrine trigger apical cardiodepression in a beta2-adrenergic receptor/Gi-dependent manner: a new model of Takotsubo cardiomyopathy. *Circulation* 2012;**126**:697–706.
121. Izumi Y, Okatani H, Shiota M, Nakao T, Ise R, Kito G, Miura K, Iwao H. Effects of metoprolol on epinephrine-induced takotsubo-like left ventricular dysfunction in non-human primates. *Hypertens Res* 2009;**32**:339–346.
122. Redmond M, Knapp C, Salim M, Shanbhag S, Jaumdally R. Use of vasopressors in Takotsubo cardiomyopathy: a cautionary tale. *Br J Anaesth* 2013;**110**:487–488.
123. Shao Y, Redfors B, Scharin Tang M, Mollmann H, Troidl C, Szardien S, Hamm C, Nef H, Boren J, Omerovic E. Novel rat model reveals important roles of beta-adrenoreceptors in stress-induced cardiomyopathy. *Int J Cardiol* 2013;**168**:1943–1950.
124. Shao Y, Redfors B, Stahlman M, Tang MS, Miljanovic A, Mollmann H, Troidl C, Szardien S, Hamm C, Nef H, Boren J, Omerovic E. A mouse model reveals an important role for catecholamine-induced lipotoxicity in the pathogenesis of stress-induced cardiomyopathy. *Eur J Heart Fail* 2013;**15**:9–22.
125. Bonacchi M, Maiani M, Harmelin G, Sani G. Intractable cardiogenic shock in stress cardiomyopathy with left ventricular outflow tract obstruction: is extra-corporeal life support the best treatment? *Eur J Heart Fail* 2009;**11**:721–727.
126. Lazzeri C, Sori A, Bernardo P, Picariello C, Gensini GF, Valente S. In-hospital refractory cardiac arrest treated with extracorporeal membrane oxygenation: a tertiary single center experience. *Acute Card Care* 2013;**15**:47–51.
127. Donker DW, Pragt E, Weerwind PW, Holtkamp JW, Vainer J, Mochtar B, Maessen JG. Rescue extracorporeal life support as a bridge to reflection in fulminant stress-induced cardiomyopathy. *Int J Cardiol* 2012;**154**:e54–e56.
128. Zegdi R, Parisot C, Sleilaty G, Deloche A, Fabiani JN. Pheochromocytoma-induced inverted Takotsubo cardiomyopathy: a case of patient resuscitation with extracorporeal life support. *J Thorac Cardiovasc Surg* 2008;**135**:434–435.
129. Santoro F, Ieva R, Ferraretti A, Ienco V, Carpanago G, Lodispoto M, Di Biase L, Di Biase M, Brunetti ND. Safety and feasibility of levosimendan administration in takotsubo cardiomyopathy: a case series. *Cardiovasc Ther* 2013;**31**:e133–e137.
130. Karvouniaris M, Papanikolaou J, Makris D, Zakyntinos E. Sepsis-associated takotsubo cardiomyopathy can be reversed with levosimendan. *Am J Emerg Med* 2012;**30**:832.e5–e7.
131. Antonini M, Stazi GV, Cirasa MT, Garotto G, Frustaci A. Efficacy of levosimendan in Takotsubo-related cardiogenic shock. *Acta Anaesthesiol Scand* 2010;**54**:119–120.
132. De Santis V, Vitale D, Tritapepe L, Greco C, Pietropaoli P. Use of levosimendan for cardiogenic shock in a patient with the apical ballooning syndrome. *Ann Intern Med* 2008;**149**:365–367.
133. Padayachee L. Levosimendan: the inotrope of choice in cardiogenic shock secondary to takotsubo cardiomyopathy? *Heart Lung Circ* 2007;**16** Suppl 3:S65–S70.
134. Cecchi E, Parodi G, Giglioli C, Passantino S, Bandinelli B, Liotta AA, Bellandi B, Cioni G, Costanzo M, Abbate R, Gensini GF, Antonucci D, Mannini L. Stress-induced hyperviscosity in the pathophysiology of takotsubo cardiomyopathy. *J Am Coll Cardiol* 2013;**111**:1523–1529.
135. Dib C, Asirvatham S, Elesber A, Rihal C, Friedman P, Prasad A. Clinical correlates and prognostic significance of electrocardiographic abnormalities in apical ballooning syndrome (Takotsubo/stress-induced cardiomyopathy). *Am Heart J* 2009;**157**:933–938.
136. Santoro F, Ieva R, Musico F, Ferraretti A, Triggiani G, Tarantino N, Biase MD, Brunetti ND. Lack of efficacy of drug therapy in preventing takotsubo cardiomyopathy recurrence: a meta-analysis. *Clin Cardiol* 2014;**37**:434–439.
137. Palla AR, Dande AS, Petrini J, Wasserman HS, Warshofsky MK. Pretreatment with low-dose beta-adrenergic antagonist therapy does not affect severity of Takotsubo cardiomyopathy. *Clin Cardiol* 2012;**35**:478–481.
138. Haghi D, Fluechter S, Suselbeck T, Kaden JJ, Borggrefe M, Papavassiliu T. Cardiovascular magnetic resonance findings in typical versus atypical forms of the acute apical ballooning syndrome (Takotsubo cardiomyopathy). *Int J Cardiol* 2007;**120**:205–211.