

Chronic endometritis in subfertile mares with presence of chlamydial DNA

Questa è la versione Post print del seguente articolo:

Original

Chronic endometritis in subfertile mares with presence of chlamydial DNA / Nervo, Tiziana; Nebbia, Patrizia; Bertero, Alessia; Robino, Patrizia; Stella, Maria Cristina; Rota, Ada; Appino, Simonetta. - In: JOURNAL OF EQUINE VETERINARY SCIENCE. - ISSN 0737-0806. - 73:(2019), pp. 91-94. [10.1016/j.jevs.2018.12.003]

Availability:

This version is available at: 11388/219511 since: 2022-05-28T11:22:54Z

Publisher:

Published

DOI:10.1016/j.jevs.2018.12.003

Terms of use:

Chiunque può accedere liberamente al full text dei lavori resi disponibili come "Open Access".

Publisher copyright

note finali coverpage

(Article begins on next page)

1 **Chronic endometritis in subfertile mares with presence of *Chlamydial* DNA**

2

3 Tiziana Nervo^a, Patrizia Nebbia^a, Alessia Bertero^c, Patrizia Robino^a, Maria Cristina Stella^a, Ada
4 Rota^a, Simonetta Appino^{b*}

5

6 ^a Department of Veterinary Sciences, University of Turin, Largo Paolo Braccini 2-5, 10095
7 Grugliasco, Italy

8 ^{b*} Department of Veterinary Medicine, University of Sassari, via Vienna 2, 07100 Sassari, Italy

9 e mail: simo@uniss.it

10 ^c Department of Veterinary Medicine, University of Milan, via dell'Università 6, 26900, Lodi, Italy

11

12 *corresponding author: Simonetta Appino, simo@uniss.it

13 ***Abstract***

14

15 When endometritis becomes chronic in mares, infertility can follow. Among various causative
16 agents, many bacteria are involved and mono- or mixed-infections are common. In our study, fifty
17 mares with a previous history of subfertility were subjected to clinical and ultrasonographic
18 examination of the reproductive tract, and samples were collected for cytology, histology,
19 bacteriology and PCR for *Chlamydia spp* detection. The aim of this work was to highlight the
20 presence of *Chlamydia abortus* in chronic endometritis of subfertile mares. Endometrial chronic
21 lesions were detected in five of six Chlamydia-positive animals.

22

23 **Keywords:** mare subfertility, chronic endometritis, *Chlamydia spp*.

24

25 **1. Introduction**

26 *Chlamydia abortus* is an obligate intracellular gram-negative bacterium that infects a large number
27 of mammalian species. It is known to be the agent of the Enzootic Ovine Abortion, but an important
28 and subtle role is represented by its involvement in genital tract infections of the bovine species,
29 causing metritis and infertility [1]. Currently, Sachse et al. adopt the classification that groups the
30 eleven *Chlamydia* species in a single genus, the genus *Chlamydia* [2]. Genital infection, occasional
31 abortion and conjunctivitis have been reported in mares but the relationship between abortion and
32 chlamydial infection is still under discussion [3]. Microorganisms belonging to the genus
33 *Chlamydia* play a role in human infertility: *Chlamydia trachomatis* is one of the main agents
34 involved in PID (Pelvic Inflammatory Disease) and can determine chronic endometritis [4]. Chronic
35 damages due to the persistence of *Chlamydia abortus* infection appear to be similar to the lesions
36 found in chronic infection by *C. trachomatis* [5] and similar, in histological aspects, to ocular
37 lesions that are found in Trachoma [6].

38 Dealing with subfertility in mares, a particular attention should be paid to chronic endometritis
39 (CE). CE often follows “post breeding endometritis”, that is a common reaction in response to
40 semen introduction into the uterus, or follows repeated artificial inseminations or intrauterine
41 treatments. Microorganisms ascending from the lower genital tract can colonize the uterine cavity;
42 in normal conditions, mechanisms such as cervical mucus plug, the endometrial epithelium and its
43 immune cellular components (neutrophils, macrophages, and natural killer cells), and elements of
44 the innate immune system, including natural antimicrobial peptides seem to play an important role
45 to restrict bacterial proliferation and invasion [7,8]. When defence mechanisms are ineffective or
46 conformation anomalies impair uterine clearance, we assist at the establishment of CE. CE consists
47 in the protraction of an inflammatory condition of uterine endometrium characterized by an
48 abnormal pattern of lymphocyte subsets and, consequently, an aberrant endometrial
49 microenvironment. Although CE can be asymptomatic, recent studies have shown that it is related

50 with repeated implantation failures after in vitro fertilization-embryo transfer, unexplained
51 infertility, and recurring abortions. [9].

52 The impossibility to identify a convincing cause of infertility, the attention at the involvement of
53 *Chlamydia abortus* in infertility in non species-specific infection, and the presence of sheep
54 (reservoir for *C. abortus*) on the grounds where the mares were housed, led us to consider the
55 presence of this microorganism among the various etiopathogenetic hypotheses.

56 The aim of this work was to highlight the presence of *Chlamydia spp* in chronic endometritis of
57 infertile mares.

58 **2. Materials and methods**

59 This study included fifty mares of various breeds, with mean age \pm SD of 12.1 \pm 4.0 years, (range 4-
60 20 years), with a previous history of infertility or subfertility, embryonal resorption, abortion. They
61 were housed in paddocks located in the area of Turin (Italy). Their reproductive tract was evaluated
62 by transrectal palpation, ultrasound (MyLabTM30Gold, Esaote, Italy) and vaginal speculum
63 examination. Samples for cytological and bacteriological exams and for DNA detection were
64 collected from all the animals. In twelve cases, when the procedure could be done in relation to the
65 breeding season, also uterine biopsies for histology were obtained. Almost all the mares had
66 conformational abnormalities but a Caslick suture had been placed to prevent ascending infections
67 of the uterus.

68 The vulva and perineal area were disinfected with povidone iodine (Betadine[®], MEDA Pharma
69 S.p.A., Milan, Italy) and all the instruments were passed through the vagina and cervix into the
70 uterus with a sterile sleeved and sterile lubricated arm. All samples were collected from the base of
71 the uterine horns.

72 A commercial uterine cytological brush (Cytobrush, Minitube, GmbH, Germany) was used to take
73 samples for cytology and DNA. For cytology, the brush was rolled on a glass slide while the brush
74 for DNA was placed in a 5 ml sterile plastic tube (Sigma-Aldrich, Milano, Italy).

75 A double-guarded cotton swab (Minitube, GmbH, Germany) was used for bacteriological exams
76 and placed in Amies medium (Copan Italia, Brescia, Italy). Uterine biopsies were collected using
77 sterilized uterine biopsy forceps (Equivet, Kruuse, Marselv, Denmark) and placed in 10% buffered
78 formalin.

79 The cell smears were fixed and stained using Diff Quick stain (Medion Diagnostics AG, Dürdingen,
80 Switzerland), following a routinary procedure [10]. Ten microscopic fields were examined (600X
81 magnification) and the number of PMNs was recorded and interpreted in accordance with the
82 classification of Le Blanc [11].

83 To demonstrate the presence of Chlamydial DNA in cytobrushes a nested-PCR based on *ompA* gene
84 [12], followed by DNA sequencing, was performed. Briefly, a DNA extraction kit (Qiagen GmbH,
85 Hilden, Germany) was used to extract DNA from each sample, in according to the manufacturer's
86 instructions. Two sets of primers based on *ompA* gene were used for the first and second step. A
87 strain of *C. psittaci* was used as a positive control in the PCR. The positive amplicons were purified
88 (ExoSAP-IT™, USB, USB, Cleveland, USA) and sequenced by a commercial resource. Finally, the
89 chlamydia species were identified by NCBI-BLAST (<http://www.ncbi.nlm.nih.gov>) search of
90 nucleotide sequences.

91 Microbiological examination was performed using a standard technique [13]. Endometrial swabs
92 were cultured on blood and MacConkey agar plates ((Beck. Dick. Comp., Maryland, USA) and
93 incubated for 48h. Miniaturized bacterial identification methods for Gram negative and positive
94 bacteria, respectively, BD BBL Crystal enteric/non fermenter ID kit and BD BBL Crystal Gram-
95 positive ID kit (Thermo Scientific, Italy) were carried out.

96 Formalin fixed biopsy were paraffin embedded; sections were then Haematoxylin and Eosin stained,
97 according to standard procedure. Histological observation was mainly focused on evidence of
98 increased stromal density, pleomorphic inflammatory infiltrate dominated by lymphocytes and
99 plasma cells, superficial stromal edema. The classification of Kenney, revised in 1986, in which

100 category II is subdivided into “a” and “b” with reference to various parameters including the degree
101 of fibrosis, was used [14].

102 Chlamydia-positive mares were treated with intrauterine oxytetracycline (Panterramicina®, Zoetis
103 Italia Srl) administered in estrous (6g for 3 days, meaning 200ml/die).

104 During the first estrus after treatment, the mares were retested for DNA detection (same procedure
105 as before: cytobrush, swab, PCR) and inseminated.

106 The study was performed in accordance with the guidelines for the care and use of animals of the
107 Department of Veterinary Science of the University of Turin, Italy.

108 **3. Results**

109 Neither clinical nor ultrasound examination of the mares revealed any sign of endometritis.

110 Cytology showed mild endometritis in twenty-four animals, moderate in three and severe in eight
111 ones. In fifteen animals no PMNs were detected. Chlamydia inclusion bodies were never detected in
112 the samples.

113 Eleven out of twelve uterine biopsies showed histological traits compatible with grade IIa
114 endometritis, mild to moderate inflammation of the endometrium and/or multifocal areas of
115 periglandular fibrosis. The inflammatory infiltrate was predominantly characterized by
116 lymphocytes. In a case a considerable number of siderocyte was observed, probably due to previous
117 hemorrhages. Histological results were in agreement with cytological findings.

118 *C. abortus* DNA was detected in six samples, one with no-lesions evidenced by cytology, four ones
119 showing a mild chronic endometritis and another one a moderate chronic endometritis (Table 1).

120 The histological findings of two of the four mild endometritis cases showed different degrees of
121 mononuclear infiltrate and slight desquamation of epithelia (Type IIa) (Fig 1).

122 Only two out of fifty endometrial swabs resulted positive to bacteriological culture. In the first
123 sample *Enterococcus faecalis* was isolated and in the second one *Staphylococcus epidermidis*. Both
124 culture-positive mares were Chlamydia-positive.

125 Four Chlamydia-positive mares were treated in the same breeding season, resulting Chlamydia-
126 negative at PCR-retest, and conceived following artificial insemination.

127 **4. Discussion**

128 Our data highlight the presence of *Chlamydia abortus* in subfertile mares affected by chronic
129 endometrial inflammation.

130 Reproductive anatomy, defective myometrial contractility, lowered immune defences,
131 overproduction of mucus, inadequate lymphatic drainage, or a combination of these factors will
132 predispose the mare to the persistence of post-breeding endometritis [8], leading to CE. Most of the
133 mares included in our study had a Caslick suture done because of conformational abnormalities,
134 thus preventing ascending contamination of the uterus. Three mares also showed acquired cervical
135 fibrosis and then uterine fluid accumulation for clearance failure.

136 Even in recent studies on women's fertility, the role of CE is getting more attention. CE in women
137 can be asymptomatic, it is found in up to 40% of infertile patients and is responsible for repeated
138 implantation failure and recurrent miscarriage [15]. The histological pattern of human CE is
139 characterised by an abnormal expression of lymphocyte subsets and, consequently, an aberrant
140 endometrial microenvironment, which play a critical role in endometrial receptivity [16]. Bacteria
141 involved in equine endometritis are for the most part considered to be opportunistic pathogens.
142 Although the bacterial equine endometritis often shows monoinfection, mixed infections do occur
143 [8]. Chlamydiae have been referred to numerous diseases in horses, among which the most
144 important clinical aspects concern abortion and respiratory tract diseases, although the
145 epidemiological and pathological aspects of the diseases and the responsible Chlamydial species
146 remain still unclear. Certainly in horse infections, the most involved species are *C. psittaci* [17] and
147 *C. pneumoniae* [18], the first one related to infections contracted by psittacides while the other is
148 controversial. It may remain for long time in the respiratory tract of horses with or without
149 symptoms and be transmitted by air flows and genital route, determine abortion in pregnant mares

150 and, perhaps, hesitate in capillary aspects such as infertility as a peripheral phenomenon.

151 *Chlamydia abortus* is well established as genitopathogenic agent in small ruminants, which are the

152 primary reservoir hosts for this organism. Its role in infertility can somehow reflect the role of

153 *Chlamydia trachomatis* in lower genital tract infections in humans, a pathogen involved in PID. The

154 clinical spectrum of chlamydial PID ranges from subclinical endometritis to frank salpingitis, tubo-

155 ovarian masses, pelvic peritonitis, periappendicitis and perihepatitis. However, symptomatic

156 chlamydial infections represent only the tip of the iceberg of all chlamydial infections, as the

157 majority of genital chlamydial infections are asymptomatic [19]. On the basis of these

158 considerations we have chosen to investigate the presence of Chlamydia in our subjects.

159 Chlamydiae are specialized in maintaining a long-term relationship with its hosts, modulating and

160 evading the immune system, thus avoiding the manifestation of markedly evident lesions, except in

161 cases of epicrisis such as abortion. While dealing with abortion often evident macroscopic lesions

162 are present, the aspects related to infertility are less evident and may represent the result of previous

163 infections that do not allow the detection of the microorganism. Wittembrick [18] did not found a

164 significant correlation between the detection of uterine Chlamydial infection and clinical sign, but

165 there was a significant association of genital Chlamydial infection and mares that were mated but

166 were not pregnant. In our work, three out of six Chlamydia-positive mares were empty since more

167 than two years and three ones showed recurrent abortions or embryo reabsorptions. Although in a

168 small number, Chlamydia-positive samples seemed to be the ones that showed the mildest lesions

169 both on histopathology and cytology. In these samples, there is always a very low degree of fibrosis

170 and the most focal aspect of the lymphocyte infiltrate. This event could suggest that the infection

171 had occurred long ago and that now only the presence of the DNA of the microorganism remains

172 detectable. The same *C. trachomatis* is able to induce subtle chronic inflammation where the

173 microorganism, in its integrity, it is no longer found, but its DNA remains indelible for a long time.

174 On the basis of cytological and histological findings and the fact that flocks of sheep had passed

175 through the fields where the mares were housed, we considered it appropriate to verify the presence
176 of this microorganism or traces of it.

177 **5. Conclusions**

178 Based on these considerations and on our results, we can point out that *C. abortus* may play a role in
179 mare's infertility, alone or in co-presence with other microorganisms. Its possible role in causing CE
180 can be worth being investigated, since its presence can somehow induce endometrial chronic
181 damage, even if mild.

182 We can suggest that, in case the standard tests have not led to a diagnosis, it could be worth testing
183 also for Chlamydial DNA through PCR, a search that that can be done from cytobrush samples,
184 especially when the history tells of a possible contact with sheep.

185 In case of detection of *C. abortus* in infertile mares, intrauterine oxytetracycline administration may
186 represent an option to increase the possibility of pregnancy.

187 The work was funded by the Italian Ministero dell'Istruzione, Università e Ricerca (ex 60% 2016).

188 **References**

189 [1] Bassan Y, Ayalon N. Abortion in dairy cows inoculated with epizootic bovine abortion agent
190 (*Chlamydia*). Am J Vet Res 1971;32:703-10.

191 [2] Sachse K, Bavoil PM, Kaltenboeck B, Stephens RS, Kuo CC, Rosselló-Móra R, et al.
192 Emendation of the family *Chlamydiaceae*: proposal of a single genus, *Chlamydia*, to include all
193 currently recognized species. Syst Appl Microbiol 2015;38:99-103.

194 [3] Rubio-Navarrete I, Montes-de-Oca-Jiménez R, Acosta-Dibarrat J. Prevalence of *Chlamydia*
195 *abortus* Antibodies in Horses From the Northern State of Mexico and Its Relationship With
196 Domestic Animals. J Equine Vet Science 2017;56:110-3.

197 [4] Mårdh PA, Møller BR, Ingerselv HJ, Nüssler E, Weström L, Wølner-Hanssen P.
198 Endometritis caused by *Chlamydia trachomatis*. Br J Vener Dis 1981; 57:191-5.

- 199 [5] Askienazy-Elbhar M, Suchet JH. Persistent “silent” *Chlamydia trachomatis* female genital
200 tract infections. *Infect Dis Obstet Gynecol* 1999;7:31-4.
- 201 [6] Derrick T, Roberts Ch, Last AR, Burr SE, Holland MJ. Trachoma and ocular Chlamydial
202 infection in the era of genomics. *Mediators Inflamm* 2015; 2015:791847.
- 203 [7] Ferris RA, McCue PM, Borlee GI, Glapa KE, Martin KH, Mangalea MR, et al. Model of
204 chronic equine endometritis involving a *Pseudomonas aeruginosa* biofilm. *Infect Immun* 2017;
205 85(12):e00332-17.
- 206 [8] Woodward EM, Troedsson MH. Inflammatory mechanisms of endometritis. *Equine Vet J*
207 2015;47:384-9.
- 208 [9] Matteo M, Cicinelli E, Greco P, Massenzio F, Baldini D, Falagario T, et al. Abnormal pattern
209 of lymphocyte subpopulations in the endometrium of infertile women with chronic endometritis.
210 *Am J Reprod Immunol* 2009; 61:322–9.
- 211 [10] Cocchia N, Paciello O, Auletta L, Uccello V, Silvestro L, Mallardo K, et al. Comparison of
212 the cytobrush, cottonswab, and low-volume uterine Flush techniques to evaluate endometrial
213 cytology for diagnosing endometritis in chronically infertile mares. *Theriogenology*
214 2012;77:89–98.
- 215 [11] LeBlanc MM. Uterine cytology. In: McKinnon AO, Squires EL, Vaala WE, Varner DD.
216 *Equine Reproduction*. 2nd ed. Wiley-Blackwell; 2011, p. 1922–8.
- 217 [12] Cahota R, Ogawa H, Mitsunashi Y, Ohya K, Yamaguchi T, Fukushi H. Genetic diversity
218 and epizootiology of *Chlamydophila psittaci* prevalent among the captive and feral avian
219 species based on VD2 region of ompA gene. *Microbiol Immunol* 2006;50:63-78.
- 220 [13] Jorgensen JH, Pfaller MA, Carroll KC, Funke G, Landry ML, Richter SS, et al. *Manual of*
221 *clinical microbiology*, Eleventh Edition. Washington DC, ASM Press 2015.
- 222 [14] Kenney RM, Doig PA. Equine endometrial biopsy. In: Morrow DA editor. *Current Therapy*
223 *in Theriogenology*. Philadelphia, WB Saunders; 1986, p. 723–9.

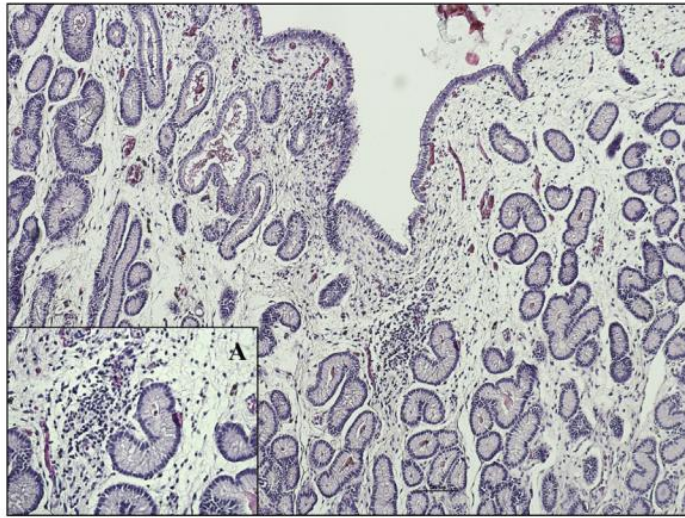
- 224 [15] Cicinelli E, Matteo M, Tinelli R, Pinto V, Marinaccio M, Indraccolo U, et al. Chronic
225 endometritis due to common bacteria is prevalent in women with recurrent miscarriage as
226 confirmed by improved pregnancy outcome after antibiotic treatment. *Reprod Sci* 2014;21:640-
227 7.
- 228 [16] Moreno I, Cicinelli E, Garcia-Grau I, Gonzalez-Monfort M, Bau D, Vilella F, et al. The
229 diagnosis of chronic endometritis in infertile asymptomatic women: a comparative study of
230 histology, microbial cultures, hysteroscopy, and molecular microbiology. *Am J Obstet Gynecol*
231 2018;218:602.
- 232 [17] Jenkins C, Jelocnik M, Micallef ML, et al. An epizootic of *Chlamydia psittaci* equine
233 reproductive loss associated with suspected spillover from native Australian parrots. *Emerg*
234 *Microbes Infect* 2018;7:88.
- 235 [18] Wittenbrink MM. Aetiological significance of chlamydial infections in equine reproductive
236 disorders. *Pferdeheilkunde* 1999;15:538-41.
- 237 [19] Malhotra M, Sood S, Mukherjee A, Muralidhar S, Bala M. Genital *Chlamydia trachomatis*:
238 An update. *Indian J Med Res* 2013;138:303-16.

Table 1

Culture, cytology, and histology results of the six Chlamydia-positive horses and breeding outcome after treatment.

N Breed	Age (y)	History	Culture	Cytology ^a	Biopsy [14]	Treatment	Posttreatment Chlamydia	PCR	Pregnancy
1 Pony	>20	Empty (>2 seasons)	Neg	Normal	2A (mild focal infiltr Inf in the spongiosum layer)	No	/	/	/
2 Standardbred	11	Embryo resorptions	Neg	Mild endometritis	/	Yes	Neg	Yes	Yes
3 Standardbred	15	Abortions Red Bag last pregnancy	<i>Enterococcus spp</i>	Mild endometritis	2A (mild fibrosis, mild Inf moder. siderocytes, spongiosum layer)	Yes	Neg	Yes	Yes
4 Standardbred	11	Empty (>2 seasons)	Neg	Moderate endometritis	/	Yes	Neg	Yes	Yes
5 Thoroughbred	11	Embryo resorptions	Neg	Mild endometritis	/	No	/	/	/
6 Standardbred	13	Empty (>2 seasons)	<i>Staphylococcus epidermidis</i>	Mild endometritis	/	Yes	Neg	Yes	Yes

Abbreviation: PCR, polymerase chain reaction; PMN, polymorphonuclear leucocyte.

^a Mild endometritis (0–2 PMN/field); moderate (3–5 PMN/field); severe (>5 PMN/field) [10].**Fig. 1.** Uterine biopsy: EE stain, 10×, mild focal mononuclear infiltrate; (A) 40× higher magnification showing of periglandular infiltrate.